A 70-year-old man comes to the office due to 3 weeks of unrelenting low back pain. He was grocery shopping when he first noticed the pain. The patient reports no trauma or leg weakness but describes having to strain to urinate. He has a history of hypertension and hyperlipidemia and has not seen a doctor in the past 5 years. His wife died a year ago, and he now lives alone. The patient is a retired construction worker and has a history of tobacco and marijuana use. There is tenderness in the lower vertebral area. Imaging study of the spine reveals several osteoblastic lesions in the lumbar vertebrae. Which of the following structures was most likely involved during the spread of this patient's disease?

A. Azygos veins
B. Internal iliac lymph nodes
C. Pampiniform plexus
D. Paraaortic lymph nodes
E. Prostatic venous plexus
F. Vertebral artery

Submit

A 70-year-old man comes to the office due to 3 weeks of unrelenting low back pain. He was grocery shopping when he first noticed the pain. The patient reports no trauma or leg weakness but describes having to strain to urinate. He has a history of hypertension and hyperlipidemia and has not seen a doctor in the past 5 years. His wife died a year ago, and he now lives alone. The patient is a retired construction worker and has a history of tobacco and marijuana use. There is tenderness in the lower vertebral area. Imaging study of the spine reveals several osteoblastic lesions in the lumbar vertebrae. Which of the following structures was most likely involved during the spread of this patient's disease?

- A. Azygos veins (1%)
- B. Internal iliac lymph nodes (24%)
- C. Pampiniform plexus (4%)
- D. Paraaortic lymph nodes (13%)
- ✓ E. Prostatic venous plexus (53%)
- F. Vertebral artery (3%)

Omitted
Correct answer
E

53%
Answered correctly

02 secs
Time Spent

04/22/2020
Last Updated

Explanation

This elderly man with new back pain, urinary symptoms, and osteoblastic lesions in the lumbar spine likely has prostate cancer with metastases to the bone. After regional lymph nodes, liver, and lungs, the skeletal system is the fourth most common site of **metastases**, which usually disseminate hematogenously. Cancers of the pelvis, including the prostate, spread to the lumbosacral spine via the **vertebral venous plexus** (VVP). The VVP communicates with a number of venous networks, including the **prostatic venous plexus**, which receives the venous supply

This elderly man with new back pain, urinary symptoms, and osteoblastic lesions in the lumbar spine likely has prostate cancer with metastases to the bone. After regional lymph nodes, liver, and lungs, the skeletal system is the fourth most common site of **metastases**, which usually disseminate hematogenously. Cancers of the pelvis, including the prostate, spread to the lumbosacral spine via the **vertebral venous plexus** (VVP). The VVP communicates with a number of venous networks, including the **prostatic venous plexus**, which receives the venous supply from the prostate, penis, and bladder. It runs up the entire spinal column and connects with the venous supply of the brain via a valveless system, which allows for bidirectional flow and regulation of intracranial pressure. This venous connection to the cerebral circulation may help explain the propensity of tumors to metastasize to the brain.

(Choices A and F) The VVP also communicates with the azygos vein in the chest, which explains in part why breast and lung cancers frequently metastasize to the thoracic spine. Similarly, due to pulmonary venous drainage into the left side of the heart, lung tumors often spread systemically via the arterial system.

(Choices B and D) Although lymph nodes are the most common sites of metastasis in general, lymphatic spread to the skeletal system is very rare.

(Choice C) The pampiniform plexus receives venous drainage from the testis, epididymis, and ductus deferens and drains into the testicular veins.

Educational objective:
The skeletal system is a common site of metastasis due to hematogenous seeding. Cancers of the pelvis, including the prostate, spread to the lumbosacral spine via the vertebral venous plexus, which in turn communicates with a number of venous networks, including the prostatic venous plexus.

References

- The cerebrospinal venous system: anatomy, physiology, and clinical implications.
- The craniospinal venous system.
- Physiopathology of spine metastasis.

Anatomy	Male Reproductive System	Prostate cancer
Subject	System	Topic

A 2-week-old boy is brought to the office for his first newborn evaluation. The boy has had persistent swelling of his left scrotum, but there has been no noticeable discomfort. Review of birth records indicates that the patient was born at 37 weeks gestation after an uncomplicated vaginal delivery. He has been breastfeeding well with normal voiding and stooling. Physical examination shows bilateral descended testicles with an enlarged, fluctuant left hemi-scrotum that transilluminates brightly. No inguinal or abdominal masses are present. The most likely cause of this patient's condition is a swelling in which of the following locations?

- A. Caput of the epididymis
- B. Cremasteric fascia
- C. External spermatic fascia
- D. Internal spermatic fascia
- E. Pampiniform plexus
- F. Tunica albuginea
- G. Tunica vaginalis

Submit

A 2-week-old boy is brought to the office for his first newborn evaluation. The boy has had persistent swelling of his left scrotum, but there has been no noticeable discomfort. Review of birth records indicates that the patient was born at 37 weeks gestation after an uncomplicated vaginal delivery. He has been breastfeeding well with normal voiding and stooling. Physical examination shows bilateral descended testicles with an enlarged, fluctuant left hemi-scrotum that transilluminates brightly. No inguinal or abdominal masses are present. The most likely cause of this patient's condition is a swelling in which of the following locations?

- A. Caput of the epididymis (1%)
- B. Cremasteric fascia (1%)
- C. External spermatic fascia (2%)
- D. Internal spermatic fascia (2%)
- E. Pampiniform plexus (8%)
- F. Tunica albuginea (9%)
- ✓ G. Tunica vaginalis (74%)

Omitted
Correct answer
G

74%
Answered correctly

01 sec
Time Spent

01/12/2020
Last Updated

Explanation

Normal anatomy | Noncommunicating hydrocele | Communicating hydrocele

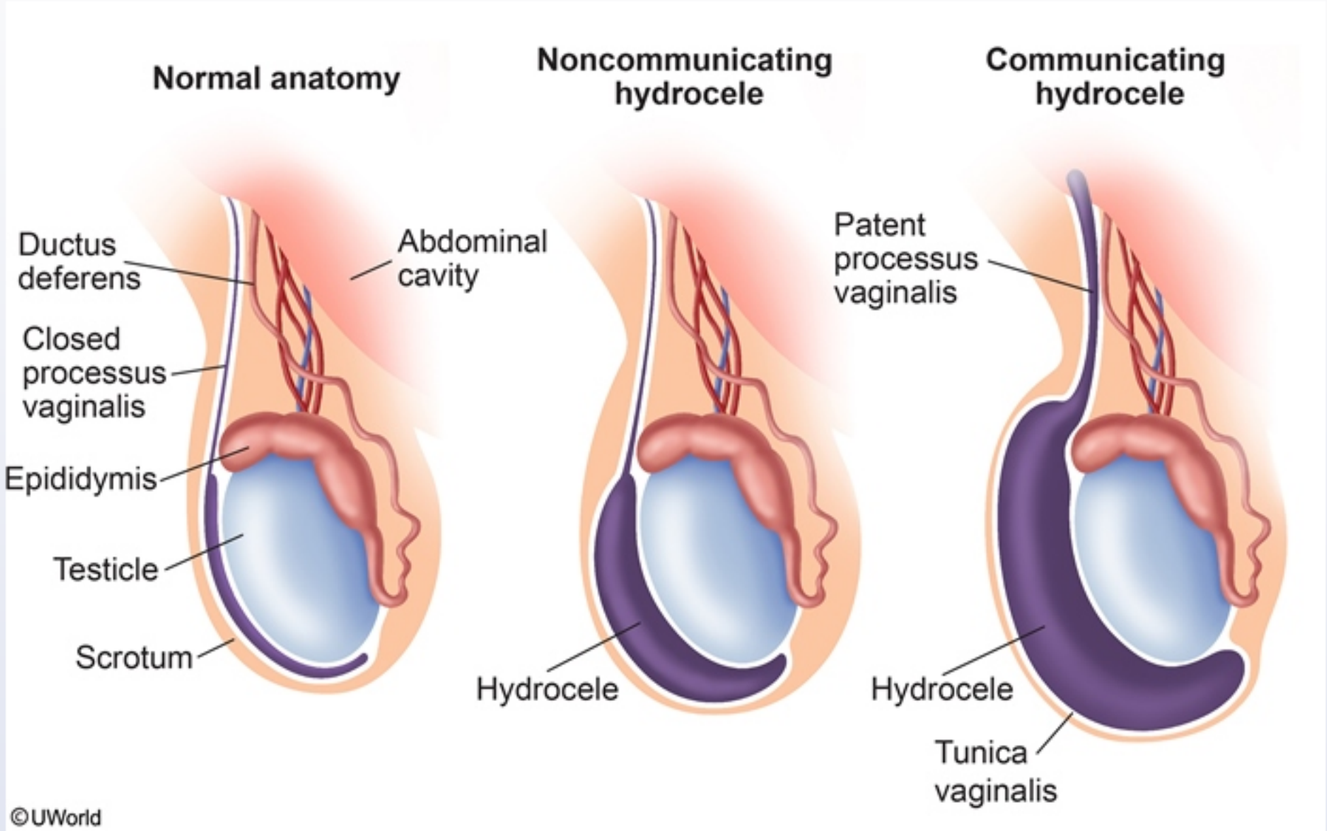

This patient's clinical presentation is consistent with a congenital, **communicating hydrocele**, a collection of **peritoneal fluid** within the **tunica vaginalis**. During embryogenesis, the testis descends through the inguinal canal, drawing with it a diverticulum of peritoneum into the scrotum. This peritoneal tissue is known as the processus vaginalis. Normally, the communication between the processus vaginalis and the peritoneum is obliterated, and the tunica vaginalis is the remaining tissue overlying the testis and epididymis. A communicating hydrocele results when the **processus vaginalis** remains **patent** and allows peritoneal fluid to accumulate in the tunica vaginalis. This type of hydrocele is common in newborns and presents as a painless scrotal swelling that transilluminates.

(Choice A) The epididymis is a coiled tube posterior to the testicle that is responsible for the storage, maturation, and transportation of sperm.

vaginalis

©UWorld

This patient's clinical presentation is consistent with a congenital, **communicating hydrocele**, a collection of **peritoneal fluid** within the **tunica vaginalis**. During embryogenesis, the testis descends through the inguinal canal, drawing with it a diverticulum of peritoneum into the scrotum. This peritoneal tissue is known as the processus vaginalis. Normally, the communication between the processus vaginalis and the peritoneum is obliterated, and the tunica vaginalis is the remaining tissue overlying the testis and epididymis. A communicating hydrocele results when the **processus vaginalis** remains **patent** and allows peritoneal fluid to accumulate in the tunica vaginalis. This type of hydrocele is common in newborns and presents as a painless scrotal swelling that transilluminates.

(Choice A) The epididymis is a coiled tube posterior to the testicle that is responsible for the storage, maturation, and transportation of sperm. The caput, or head, of the epididymis is the superior-most aspect of the tube that stores sperm prior to maturation. Inflammation of the epididymis, or epididymitis, is classically associated with *Gonorrhea* and *Chlamydia* infection.

(Choices B, C, and D) The spermatic cord is a collection of structures that originate in the abdominal cavity and course downward toward the testes. It is covered by 3 layers: internal spermatic fascia, cremasteric fascia, and external spermatic fascia. The internal spermatic fascia immediately overlies the spermatic cord and is derived from the transversalis fascia. The cremasteric fascia arises from the internal oblique abdominal muscle. The external spermatic fascia is derived from the external oblique abdominal muscle. This is the outermost layer of the spermatic cord and lies deep to the dartos muscle and scrotal fascia.

(Choice E) The pampiniform plexus is a collection of veins within the spermatic cord. Distension of these veins leads to a varicocele and is clinically described as a palpable "bag of worms."

(Choice F) The tunica albuginea is the fibrous tissue that immediately overlies the testicles (ie, beneath the tunica vaginalis) and the corpora cavernosa of the penis. In Peyronie disease, excess collagen formation within the tunica albuginea can cause significant pain and curvature of the penis.

Educational objective:
A communicating hydrocele results when serous fluid accumulates within the tunica vaginalis in the setting of a patent processus vaginalis. It presents as a painless swelling that transilluminates on examination.

References

Evaluation of scrotal masses

(Choice A) The epididymis is a coiled tube posterior to the testicle that is responsible for the storage, maturation, and transportation of sperm. The caput, or head, of the epididymis is the superior-most aspect of the tube that stores sperm prior to maturation. Inflammation of the epididymis, or epididymitis, is classically associated with *Gonorrhea* and *Chlamydia* infection.

(Choices B, C, and D) The spermatic cord is a collection of structures that originate in the abdominal cavity and course downward toward the testes. It is covered by 3 layers: internal spermatic fascia, cremasteric fascia, and external spermatic fascia. The internal spermatic fascia immediately overlies the spermatic cord and is derived from the transversalis fascia. The cremasteric fascia arises from the internal oblique abdominal muscle. The external spermatic fascia is derived from the external oblique abdominal muscle. This is the outermost layer of the spermatic cord and lies deep to the dartos muscle and scrotal fascia.

(Choice E) The pampiniform plexus is a collection of veins within the spermatic cord. Distension of these veins leads to a varicocele and is clinically described as a palpable "bag of worms."

(Choice F) The tunica albuginea is the fibrous tissue that immediately overlies the testicles (ie, beneath the tunica vaginalis) and the corpora cavernosa of the penis. In Peyronie disease, excess collagen formation within the tunica albuginea can cause significant pain and curvature of the penis.

Educational objective:
A communicating hydrocele results when serous fluid accumulates within the tunica vaginalis in the setting of a patent processus vaginalis. It presents as a painless swelling that transilluminates on examination.

References

- Evaluation of scrotal masses.
- Hernias and hydroceles.

Anatomy	Male Reproductive System	Hydrocele
Subject	System	Topic

Copyright © UWorld. All rights reserved.

testicle

Exhibit Display

Zoom In | Zoom Out | Reset | Add To New Card | Existing Card

Exhibit Display

Zoom In Zoom Out Reset Add To New Card | Existing Card

Exhibit Display

Spermatic cord layers

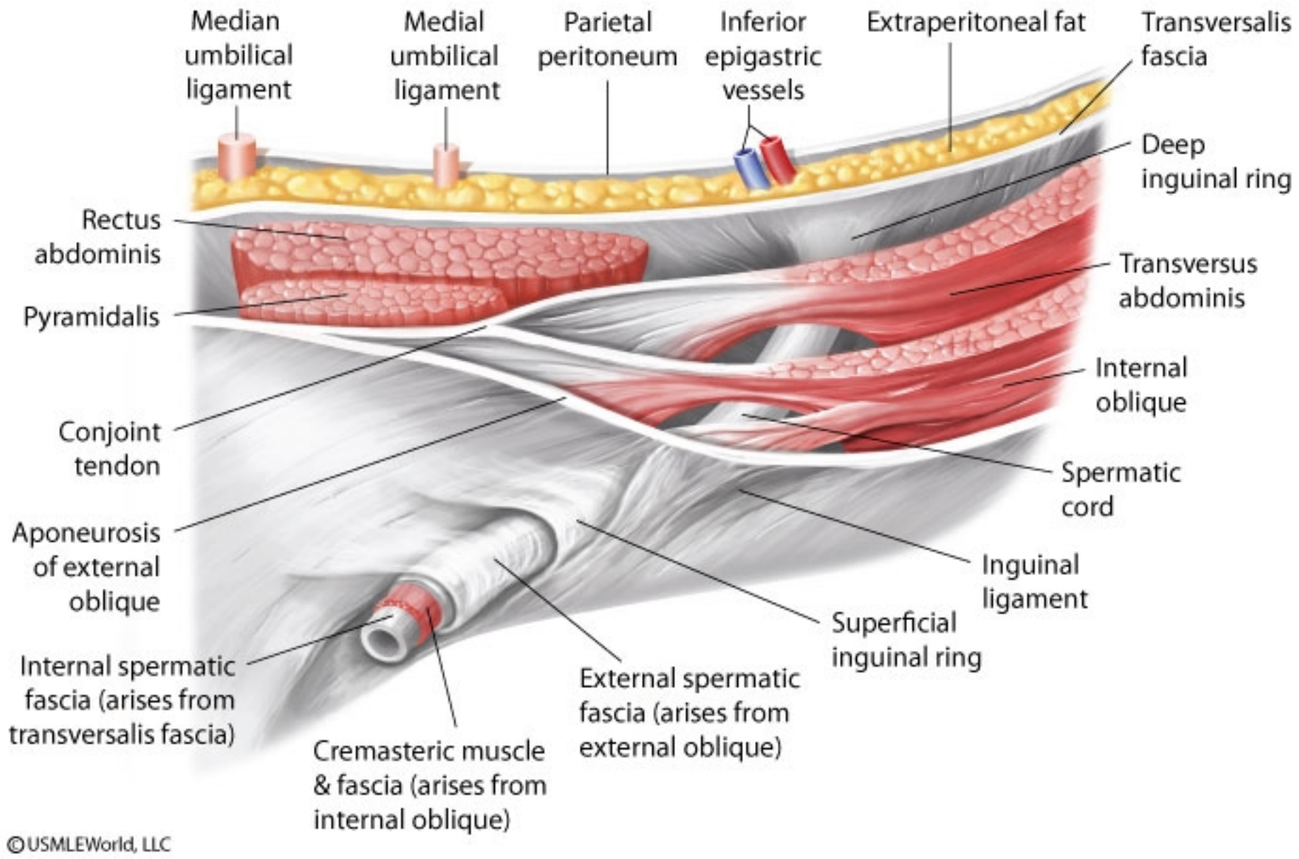

©USMLEWorld, LLC

Zoom In | Zoom Out | Reset | Add To New Card | Existing Card

A 63-year-old woman comes to the office for evaluation of chronic constipation. For the past 8 months, the patient has had increased straining with bowel movements but no abdominal pain or rectal bleeding. She has 2 children, both delivered via forceps-assisted vaginal delivery. BMI is 31 kg/m^2. On digital rectal examination, there are no masses and rectal tone is normal; pelvic examination shows a visible bulge into the vagina with straining. Sensation around the perineum is intact. Fecal occult blood testing is negative. Which of the following is the most likely cause of this patient's symptoms?

A. Absence of colonic intramural ganglion cells

B. Colonic sensitivity with chronic irregular contractions

C. Damage to the levator ani muscle complex

D. Defect in the external anal sphincter

E. Increased internal anal sphincter parasympathetic tone

Submit

A 63-year-old woman comes to the office for evaluation of chronic constipation. For the past 8 months, the patient has had increased straining with bowel movements but no abdominal pain or rectal bleeding. She has 2 children, both delivered via forceps-assisted vaginal delivery. BMI is 31 kg/m^2. On digital rectal examination, there are no masses and rectal tone is normal; pelvic examination shows a visible bulge into the vagina with straining. Sensation around the perineum is intact. Fecal occult blood testing is negative. Which of the following is the most likely cause of this patient's symptoms?

- A. Absence of colonic intramural ganglion cells (2%)
- B. Colonic sensitivity with chronic irregular contractions (3%)
- ✓ C. Damage to the levator ani muscle complex (78%)
- D. Defect in the external anal sphincter (7%)
- E. Increased internal anal sphincter parasympathetic tone (7%)

Omitted
Correct answer
C

78%
Answered correctly

02 secs
Time Spent

04/08/2020
Last Updated

Explanation

Rectocele, prolapse of posterior vaginal wall

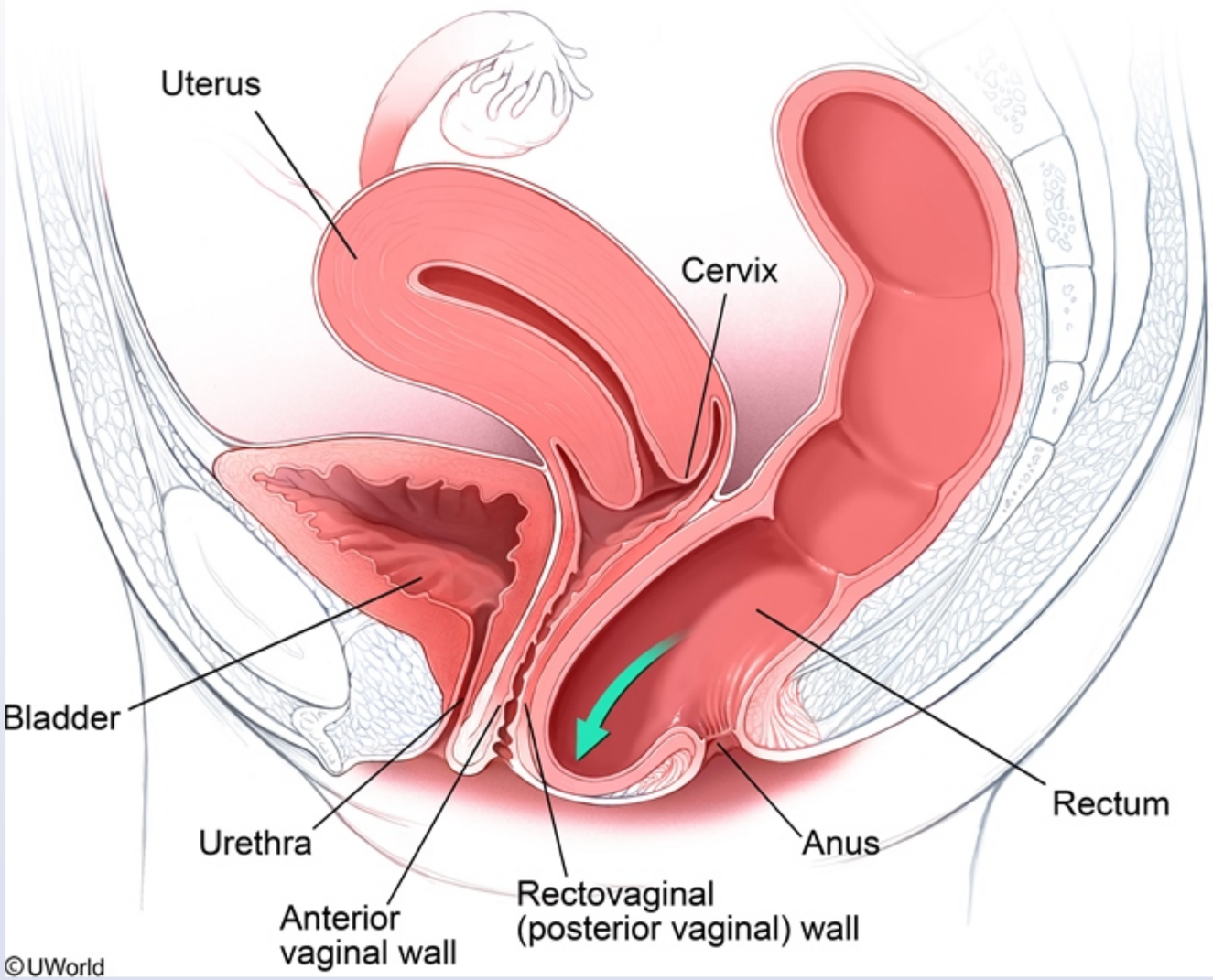

This patient's chronic constipation is caused by **pelvic organ prolapse**, the herniation of pelvic organs (eg, bladder, rectum) into the vaginal wall

©UWorld

This patient's chronic constipation is caused by **pelvic organ prolapse**, the herniation of pelvic organs (eg, bladder, rectum) into the vaginal wall due to **levator ani muscle complex damage**. The levator ani muscle complex forms most of the pelvic floor and functions to hold the pelvic organs in a stable position; when this complex is damaged, such as with increased intraabdominal pressure (eg, **pregnancy**, obesity) or obstetric trauma (eg, forceps-assisted vaginal delivery), there is increased pelvic floor laxity, resulting in decreased pelvic organ support.

The decreased pelvic floor support causes an anatomic change to normal pelvic organ positions; for the rectum, this leads to a change in rectal angle during defecation, which can cause incomplete defecation and **constipation**. With accumulation of fecal material, the rectum expands and herniates through the rectovaginal septum, causing **prolapse of the rectum** into the **posterior vaginal wall** (ie, **rectocele**). The prolapse is exacerbated by Valsalva maneuvers (eg, **vaginal bulge while straining**), which cause further difficulty with defecation; therefore, some patients apply digital pressure against the prolapse (ie, **splinting**) to help improve bowel movements.

(Choice A) Hirschsprung disease, the absence of colonic intramural ganglion cells due to failed neural crest cell migration, typically presents in infants. It causes constipation and increased rectal tone due to the inability of the aganglionic segment to relax.

(Choice B) Irritable bowel syndrome (IBS) is often associated with chronic irregular luminal contractions and increased gastrointestinal tract sensitivity. It typically presents with recurrent abdominal pain and either diarrhea or constipation. IBS does not affect the pelvic floor musculature and, therefore, does not cause a vaginal bulge.

(Choice D) An external anal sphincter defect occurs with a perineal laceration, a common complication of vaginal deliveries; however, patients typically have decreased rectal tone (not seen here) that can result in anal incontinence (ie, involuntary loss of flatus or fecal material).

(Choice E) The internal anal sphincter (IAS) is under tonic contraction via sympathetic fibers; contraction is inhibited by parasympathetic fibers. Increased IAS parasympathetic tone would cause sphincter relaxation and an increased urge to defecate rather than chronic constipation.

Educational objective:
Pelvic organ prolapse, the herniation of pelvic organs (eg, rectum) into the vagina, occurs due to damage to the levator ani muscle complex. Patients with prolapse of the posterior vaginal wall (ie, rectocele) classically have chronic constipation and a vaginal bulge.

References

- Functional disorders: rectocele.

©UWorld

Exhibit Display

Hirschsprung disease

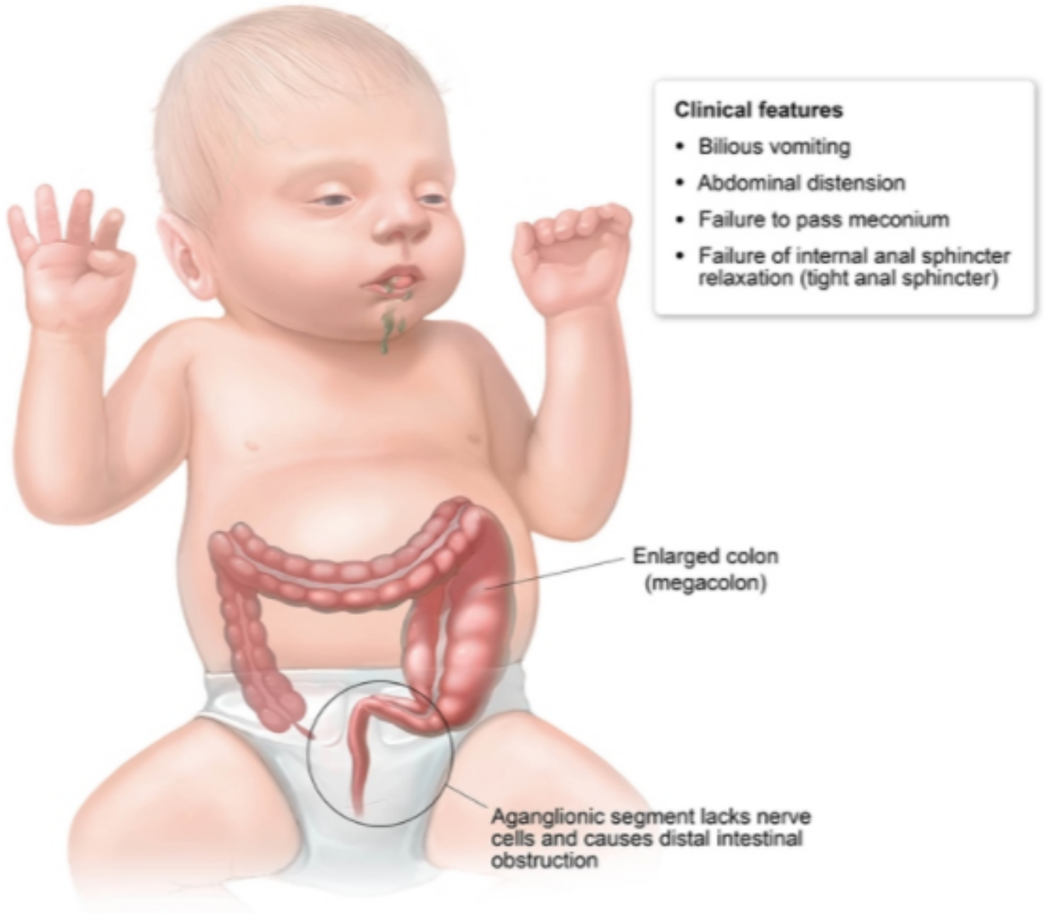

©UWorld

Zoom In Zoom Out Reset Add To Flash Card

©UWorld

Exhibit Display

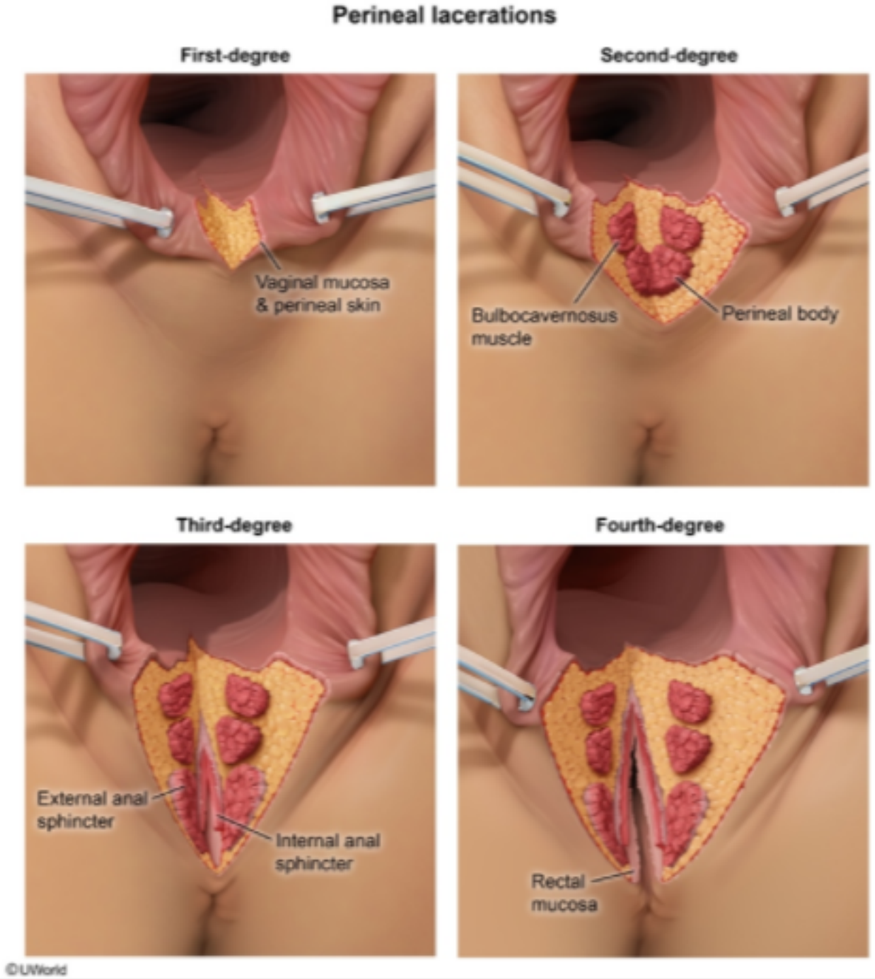

Zoom In
Zoom Out
Reset
Add To Flash Card

A 63-year-old man comes to the office due to poor urine flow for several months. The patient says that it takes about 10 seconds to initiate a urinary stream. He also needs to strain when urinating or the stream "just stops before the bladder is empty." He has tried behavioral modifications, but the symptoms continue to be bothersome. The patient takes lisinopril for hypertension. He has smoked a pack of cigarettes a day for 30 years. His father had urothelial cancer of the bladder. He reports significant improvement several months after starting finasteride. A drug effect on which of the following structures is most likely responsible for the improvement in this patient's symptoms?

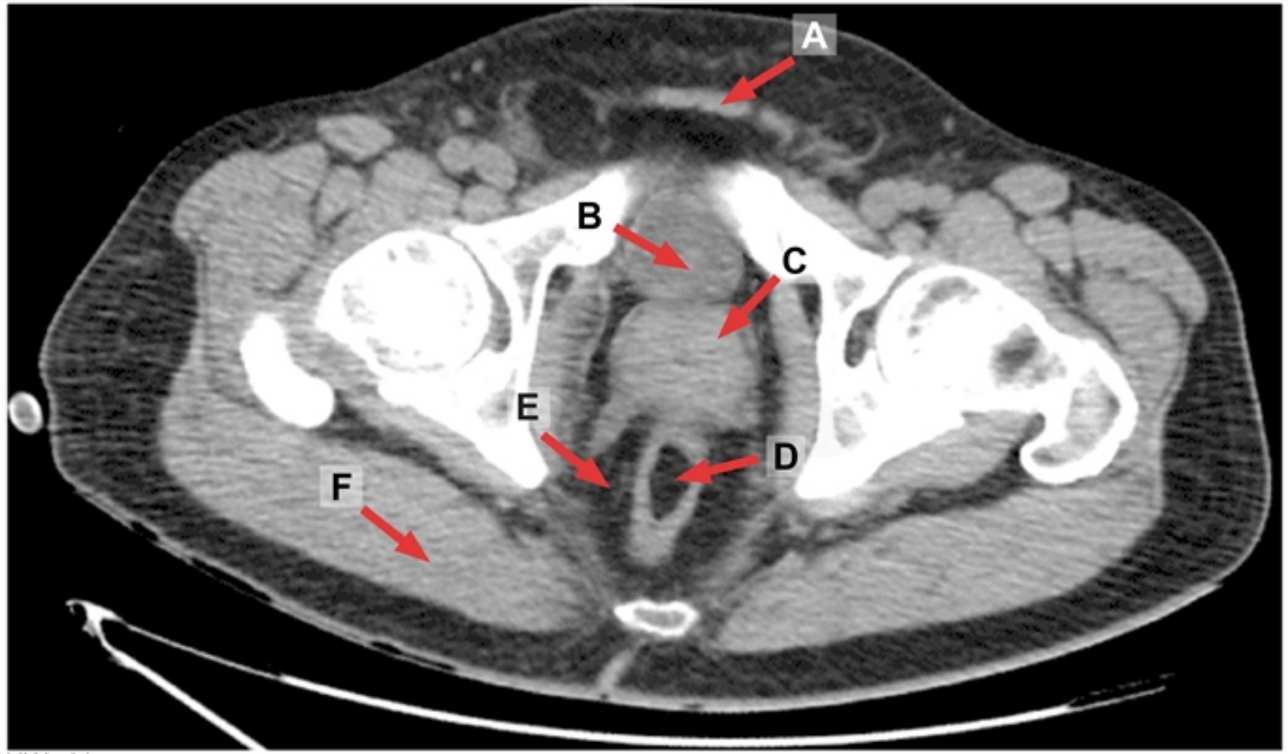

©UWorld

A. A

B. B

1
2
3
4
5
6
7
8
9
10
11
12
13
14
15
16
17
18
19
20
21
22

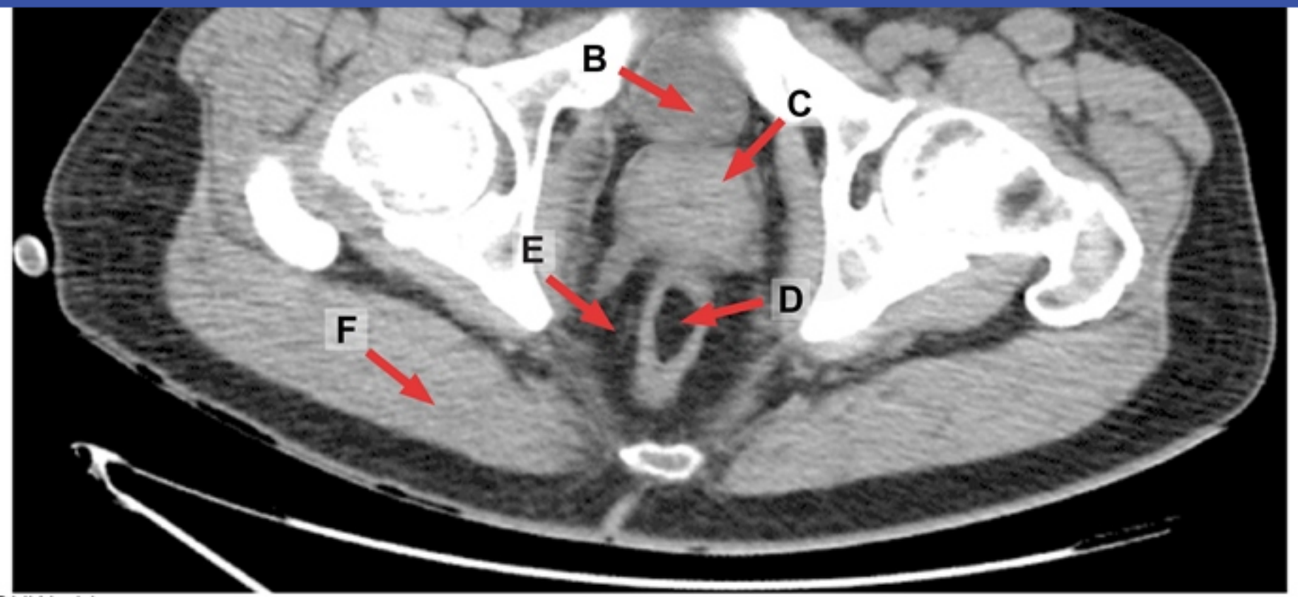

©UWorld

A. A

B. B

C. C

D. D

E. E

F. F

Submit

1
2
3
4
5
6
7
8
9
10
11
12
13
14
15
16
17
18
19
20
21
22

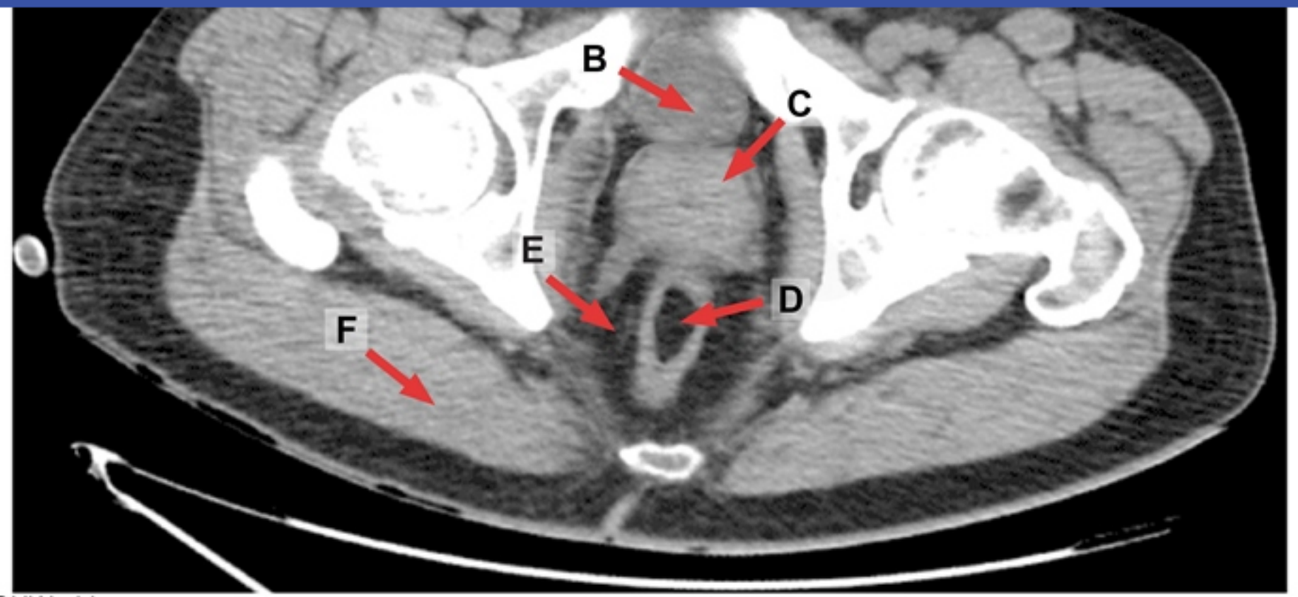

©UWorld

A. A (1%)
B. B (23%)
✓ C. C (68%)
D. D (2%)
E. E (3%)
F. F (0%)

Omitted
Correct answer

68%
Answered correctly

07 secs
Time Spent

06/09/2020
Last Updated

Prostatic hyperplasia

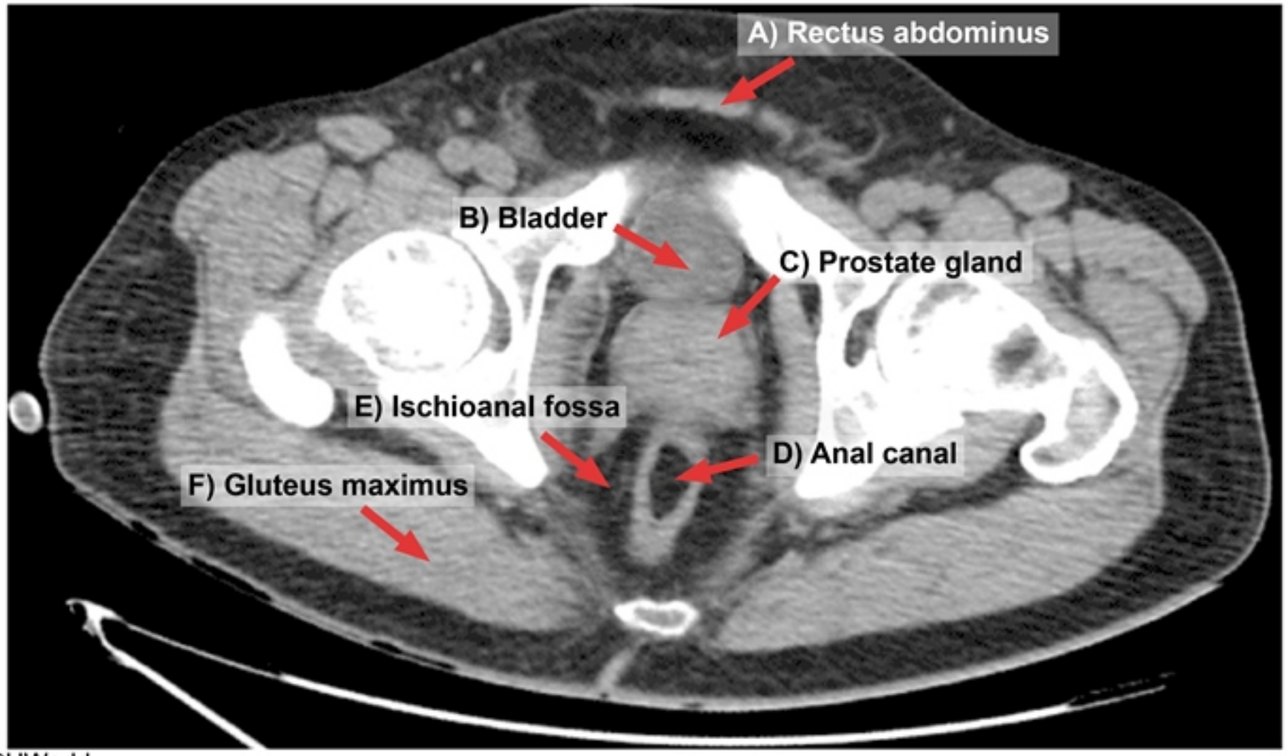

©UWorld

This patient has signs of **bladder outlet obstruction** (eg, urinary hesitancy, need to strain) most likely due to benign prostatic hyperplasia (BPH), a condition that is present in >90% of men age ≥80. The diagnosis is based on history and digital rectal examination showing a smooth, homogenously enlarged prostate. The prostate is located just anterior to the anal canal **(Choice D)** and posterior to the symphyses pubis (not visible on the CT scan image shown above).

BPH may cause **static** urinary obstruction (androgen-mediated enlargement of the prostate) or **dynamic** obstruction (prostate smooth muscle contraction via α-adrenoceptors). 5-α reductase inhibitors (eg, finasteride) inhibit the action of androgens on the prostate gland, preventing the conversion of testosterone to dihydrotestosterone and thereby limiting further prostate enlargement. α-adrenergic blockers (eg, tamsulosin) relax

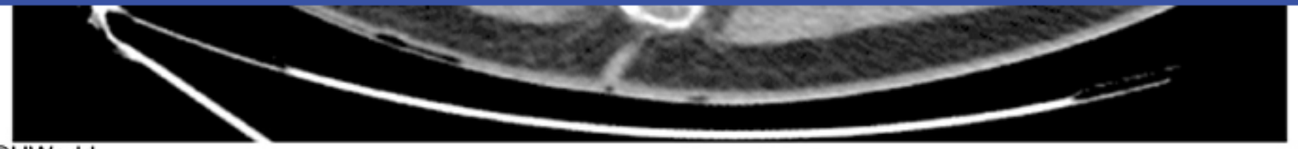

©UWorld

This patient has signs of **bladder outlet obstruction** (eg, urinary hesitancy, need to strain) most likely due to benign prostatic hyperplasia (BPH), a condition that is present in >90% of men age ≥80. The diagnosis is based on history and digital rectal examination showing a smooth, homogenously enlarged prostate. The prostate is located just anterior to the anal canal **(Choice D)** and posterior to the symphyses pubis (not visible on the CT scan image shown above).

BPH may cause **static** urinary obstruction (androgen-mediated enlargement of the prostate) or **dynamic** obstruction (prostate smooth muscle contraction via α-adrenoceptors). 5-α reductase inhibitors (eg, finasteride) inhibit the action of androgens on the prostate gland, preventing the conversion of testosterone to dihydrotestosterone and thereby limiting further prostate enlargement. α-adrenergic blockers (eg, tamsulosin) relax the smooth muscle in the bladder neck and prostate gland and are also used to control symptoms of BPH.

(Choice B) The distal end of the anterior bladder wall may or may not be visible at this level depending on patient positioning and bladder filling.

Educational objective:
The prostate is located between the pubic symphysis and the anal canal and is visible on inferior sections of the pelvis on CT scan. Benign prostatic hyperplasia is a common, age-related condition that causes urinary symptoms (eg, hesitancy, straining, incomplete voiding). It can be medically treated with α-adrenergic blockers and 5-α reductase inhibitors.

References

- Alpha blockers for the treatment of benign prostatic hyperplasia.
- Pathophysiology of benign prostatic hyperplasia: insights from medical therapy for the disease.

Anatomy	Male Reproductive System	Benign prostatic hyperplasia
Subject	System	Topic

Copyright © UWorld. All rights reserved.

A 31-year-old man comes to the emergency department complaining of right-sided scrotal pain and swelling that has gradually worsened over the last 3 days. His temperature is 38.3 C (101 F). On physical examination, his right hemiscrotum is warm, tender, and erythematous. The cremasteric reflex is present. A scrotal ultrasound reveals a fluid collection consistent with a superficial scrotal abscess. Which of the following lymph node groups is most likely to be tender and swollen?

A. Common iliac
B. Inferior mesenteric
C. Infraclavicular
D. Para-aortic
E. Superficial inguinal

Submit

A 31-year-old man comes to the emergency department complaining of right-sided scrotal pain and swelling that has gradually worsened over the last 3 days. His temperature is 38.3 C (101 F). On physical examination, his right hemiscrotum is warm, tender, and erythematous. The cremasteric reflex is present. A scrotal ultrasound reveals a fluid collection consistent with a superficial scrotal abscess. Which of the following lymph node groups is most likely to be tender and swollen?

- A. Common iliac (2%)
- B. Inferior mesenteric (1%)
- C. Infraclavicular (0%)
- D. Para-aortic (23%)
- ✓ E. Superficial inguinal (71%)

Omitted
Correct answer
E

71%
Answered correctly

02 secs
Time Spent

01/30/2020
Last Updated

Explanation

Lymph vessels & nodes of male genitalia

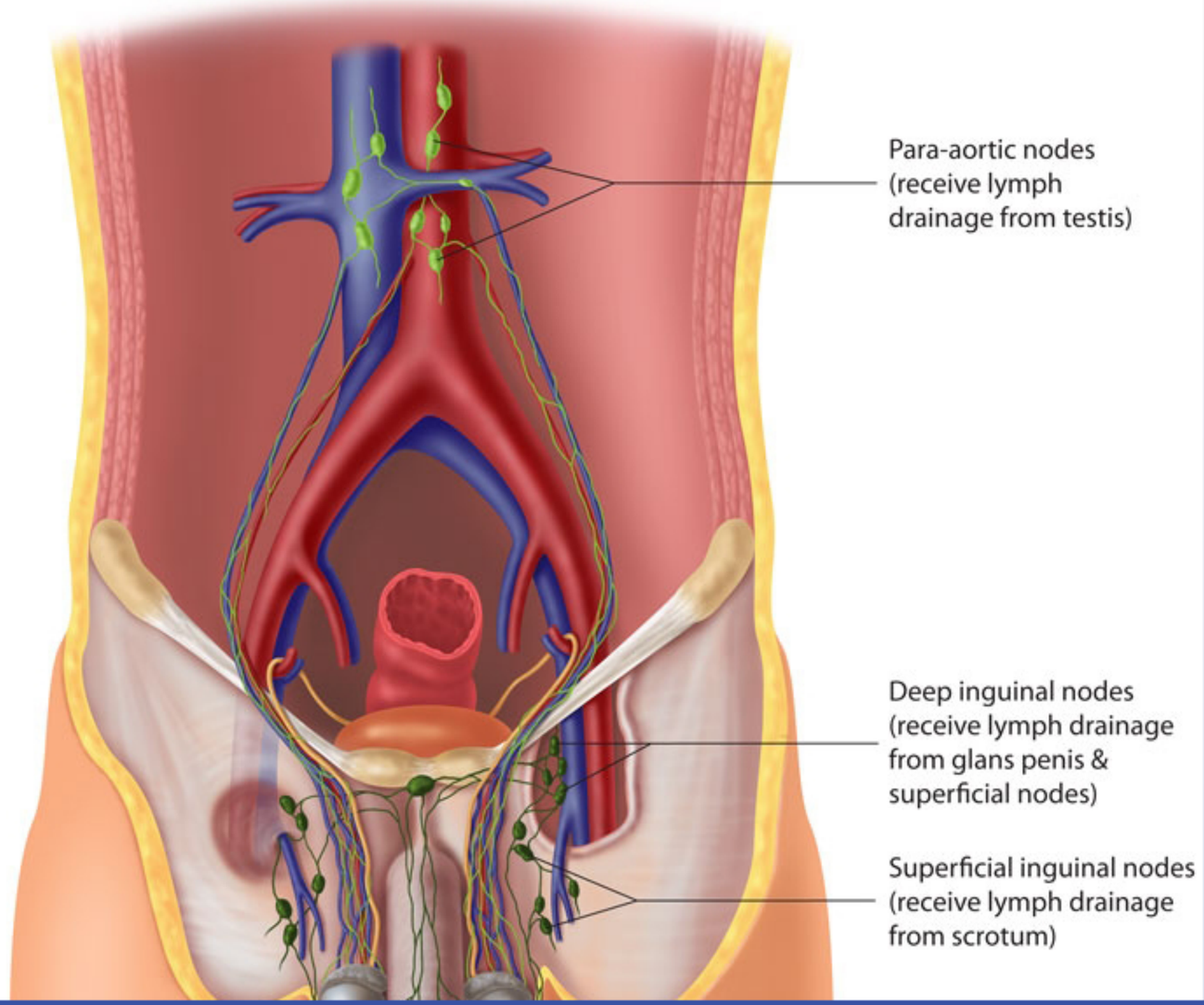

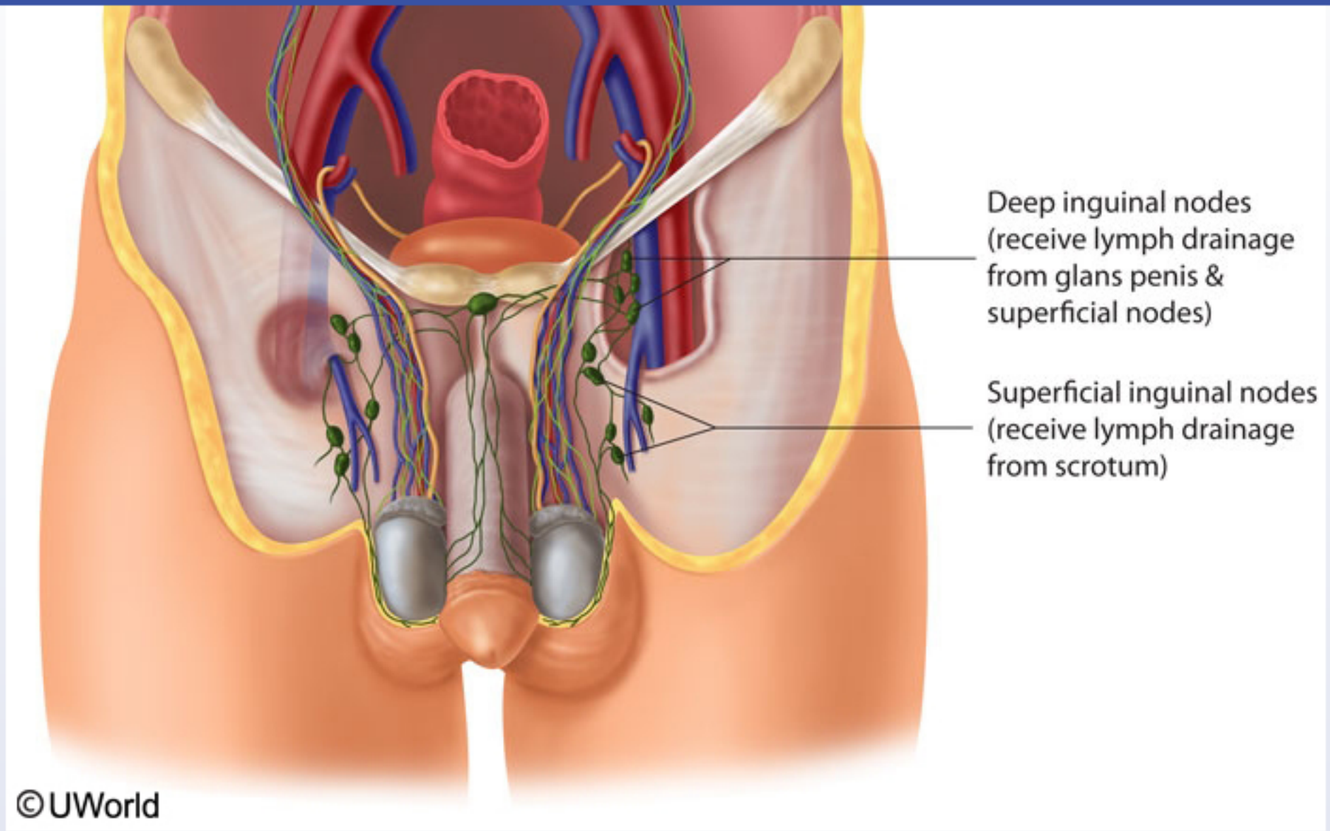

Lymphatic drainage of the scrotum occurs via the superficial inguinal lymph nodes. These lymph nodes drain nearly all cutaneous lymph from the umbilicus to the feet, including the external genitalia and anus (up to the dentate line). The exceptions are the testis, glans penis, and the cutaneous portion of the posterior calf. Lymph from the testes drains directly into the para-aortic (retroperitoneal) lymph nodes **(Choice D)**. Lymph from the glans penis and the cutaneous portion of the posterior calf drains into the deep inguinal lymph nodes. The superficial inguinal lymph nodes also drain into the deep inguinal lymph nodes.

(Choice A) The common iliac nodes are located alongside the common iliac artery and drain the internal and external iliac nodes. The external iliac nodes receive lymph from the deep inguinal lymph nodes.

(Choice B) The inferior mesenteric nodes drain the structures supplied by branches of the inferior mesenteric artery (eg, the left colic, sigmoid

Lymphatic drainage of the scrotum occurs via the superficial inguinal lymph nodes. These lymph nodes drain nearly all cutaneous lymph from the umbilicus to the feet, including the external genitalia and anus (up to the dentate line). The exceptions are the testis, glans penis, and the cutaneous portion of the posterior calf. Lymph from the testes drains directly into the para-aortic (retroperitoneal) lymph nodes **(Choice D)**. Lymph from the glans penis and the cutaneous portion of the posterior calf drains into the deep inguinal lymph nodes. The superficial inguinal lymph nodes also drain into the deep inguinal lymph nodes.

(Choice A) The common iliac nodes are located alongside the common iliac artery and drain the internal and external iliac nodes. The external iliac nodes receive lymph from the deep inguinal lymph nodes.

(Choice B) The inferior mesenteric nodes drain the structures supplied by branches of the inferior mesenteric artery (eg, the left colic, sigmoid, and superior rectal arteries). Thus, these nodes drain the descending and sigmoid colon as well as the upper part of the rectum, and their efferents drain into the pre-aortic nodes.

(Choice C) Infraclavicular lymph nodes are found beside the cephalic vein between the pectoralis major and deltoid, immediately below the clavicle. They drain lymph from portions of the upper limb and breast.

Educational objective:
Due to its intra-abdominal origin, lymphatic drainage of the testis is to the para-aortic lymph nodes. In contrast, lymph drainage from the scrotum goes into the superficial inguinal lymph nodes.

Anatomy	Male Reproductive System	Lymphatic drainage
Subject	System	Topic

Copyright © UWorld. All rights reserved.

A 62-year-old man comes to the office due to an elevated prostate-specific antigen level on a screening test. When asked about genitourinary symptoms, the patient says, "It often takes a bit of time before my urine starts flowing," but he has no other problems. Abdominal and external genital examinations are unremarkable. Digital rectal examination reveals hard prostate nodules. A biopsy confirms adenocarcinoma, and the patient undergoes a radical prostatectomy. During the surgery, the nerves within the fascia surrounding the gland are inadvertently injured. Which of the following is the most likely consequence of the nerve injury?

A. Detrusor muscle overactivity

B. Erectile dysfunction

C. External urethral sphincter paralysis

D. Fecal incontinence

E. Loss of cremasteric reflex

F. Loss of penile skin sensation

Submit

A 62-year-old man comes to the office due to an elevated prostate-specific antigen level on a screening test. When asked about genitourinary symptoms, the patient says, "It often takes a bit of time before my urine starts flowing," but he has no other problems. Abdominal and external genital examinations are unremarkable. Digital rectal examination reveals hard prostate nodules. A biopsy confirms adenocarcinoma, and the patient undergoes a radical prostatectomy. During the surgery, the nerves within the fascia surrounding the gland are inadvertently injured. Which of the following is the most likely consequence of the nerve injury?

- A. Detrusor muscle overactivity (5%)
- ✓ B. Erectile dysfunction (57%)
- C. External urethral sphincter paralysis (16%)
- D. Fecal incontinence (6%)
- E. Loss of cremasteric reflex (8%)
- F. Loss of penile skin sensation (4%)

Omitted
Correct answer
B

57%
Answered correctly

02 secs
Time Spent

06/23/2020
Last Updated

Explanation

1
2
3
4
5
6
7
8
9
10
11
12
13
14
15
16
17
18
19
20
21
22

Pelvic autonomic nerves

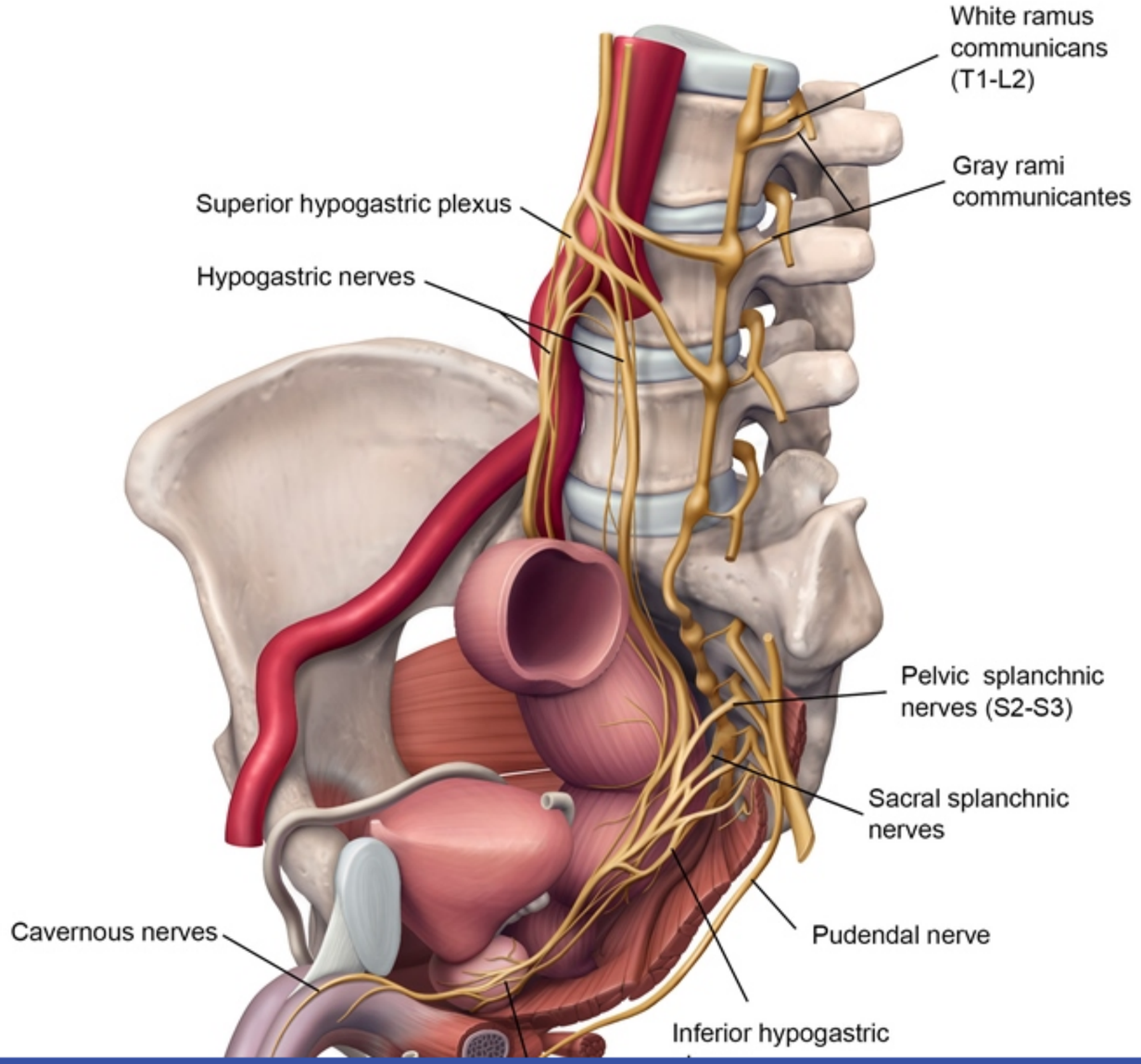

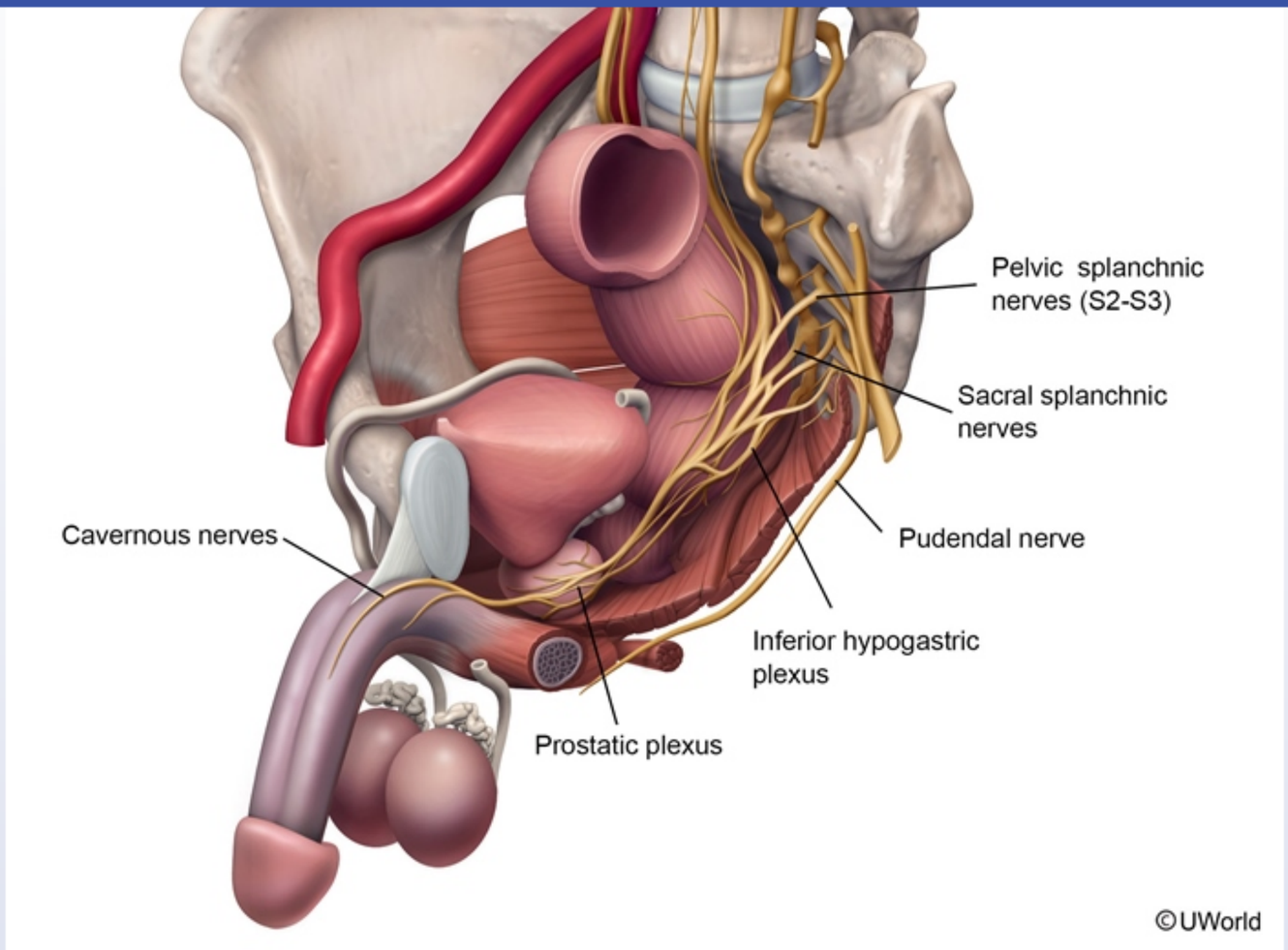

The **prostatic plexus** lies within the fascia of the prostate and originates from the **inferior hypogastric plexus** (which itself is a continuation of the hypogastric nerve with additional input from the **pelvic and sacral splanchnic nerves**). The lesser and greater **cavernous nerves** arise from the prostatic plexus and pass beneath the pubic arch to innervate the corpora cavernosa of the penis and urethra. The cavernous nerves carry post-ganglionic parasympathetic fibers that facilitate penile erection. **Prostatectomy** or injury to the prostatic plexus can cause **erectile dysfunction**; as a result, surgeons attempt to preserve the integrity of the prostatic fascial shell during surgery.

The **prostatic plexus** lies within the fascia of the prostate and originates from the **inferior hypogastric plexus** (which itself is a continuation of the hypogastric nerve with additional input from the **pelvic and sacral splanchnic nerves**). The lesser and greater **cavernous nerves** arise from the prostatic plexus and pass beneath the pubic arch to innervate the corpora cavernosa of the penis and urethra. The cavernous nerves carry post-ganglionic parasympathetic fibers that facilitate penile erection. **Prostatectomy** or injury to the prostatic plexus can cause **erectile dysfunction**; as a result, surgeons attempt to preserve the integrity of the prostatic fascial shell during surgery.

(Choice A) Detrusor muscle overactivity leads to urge incontinence, which is more common in women. The detrusor muscle is controlled by parasympathetic fibers from the pelvic splanchnic nerves and inferior hypogastric plexus, which are not usually injured during prostatectomy.

(Choices C, D, and F) Branches of the pudendal nerve innervate the external urethral and anal sphincters. They also provide sensory innervation of the external genitalia. Pudendal nerve injury can lead to fecal incontinence, decreased penile sensation, or external urethral sphincter paralysis. Although urethral muscle injury can occur during prostate surgery, injury to the main pudendal nerve is less common with prostatectomy.

(Choice E) The cremasteric reflex is elicited by lightly stroking the medial thigh, which causes contraction of the cremaster muscle to pull up the ipsilateral testis. This reflex is mediated by the genitofemoral nerve, which originates from the L1-L2 spinal nerves. Loss of the cremasteric reflex is most commonly seen with testicular torsion or L1-L2 spinal injury.

Educational objective:
The prostatic plexus (inferior hypogastric nerves plus pelvic and sacral splanchnic nerves) lies within the fascia of the prostate and innervates the corpus cavernosa of the penis, which facilitates penile erection. As a result, prostatectomy or injury to the prostatic plexus can cause erectile dysfunction.

References

- Optimizing postoperative sexual function after radical prostatectomy.

Anatomy	Male Reproductive System	Male sexual dysfunction
Subject	System	Topic

Copyright © UWorld. All rights reserved.

A 28-year-old woman, gravida 1, para 0, goes into labor at 38 weeks gestation. During the second stage, as the patient is pushing, the fetus develops a nonreassuring fetal heart rate. A midline episiotomy is performed to expedite delivery. A vertical, midline incision is made at the posterior vaginal opening through the vaginal and subvaginal mucosa. Which of the following structures is most likely involved in this incision?

- A. External anal sphincter
- B. Ischiocavernosus muscle
- C. Levator ani muscle
- D. Perineal body
- E. Rectal mucosa
- F. Transverse perineal muscle

Submit

A 28-year-old woman, gravida 1, para 0, goes into labor at 38 weeks gestation. During the second stage, as the patient is pushing, the fetus develops a nonreassuring fetal heart rate. A midline episiotomy is performed to expedite delivery. A vertical, midline incision is made at the posterior vaginal opening through the vaginal and subvaginal mucosa. Which of the following structures is most likely involved in this incision?

- A. External anal sphincter (7%)
- B. Ischiocavernosus muscle (5%)
- C. Levator ani muscle (17%)
- ✓ D. Perineal body (48%)
- E. Rectal mucosa (2%)
- F. Transverse perineal muscle (17%)

Omitted
Correct answer
D

48%
Answered correctly

02 secs
Time Spent

01/26/2020
Last Updated

Explanation

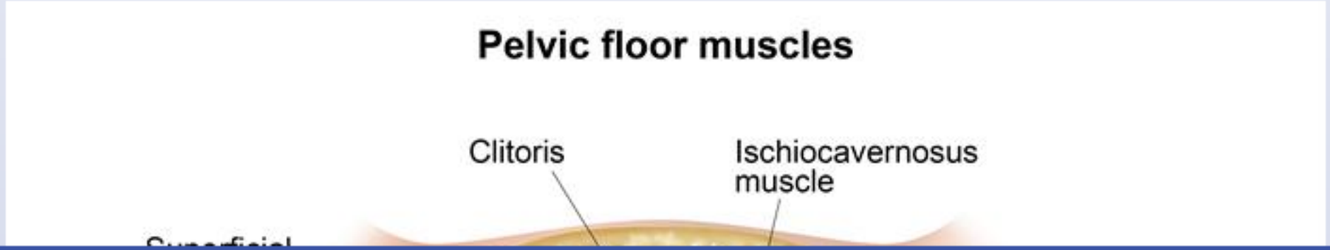

Pelvic floor muscles

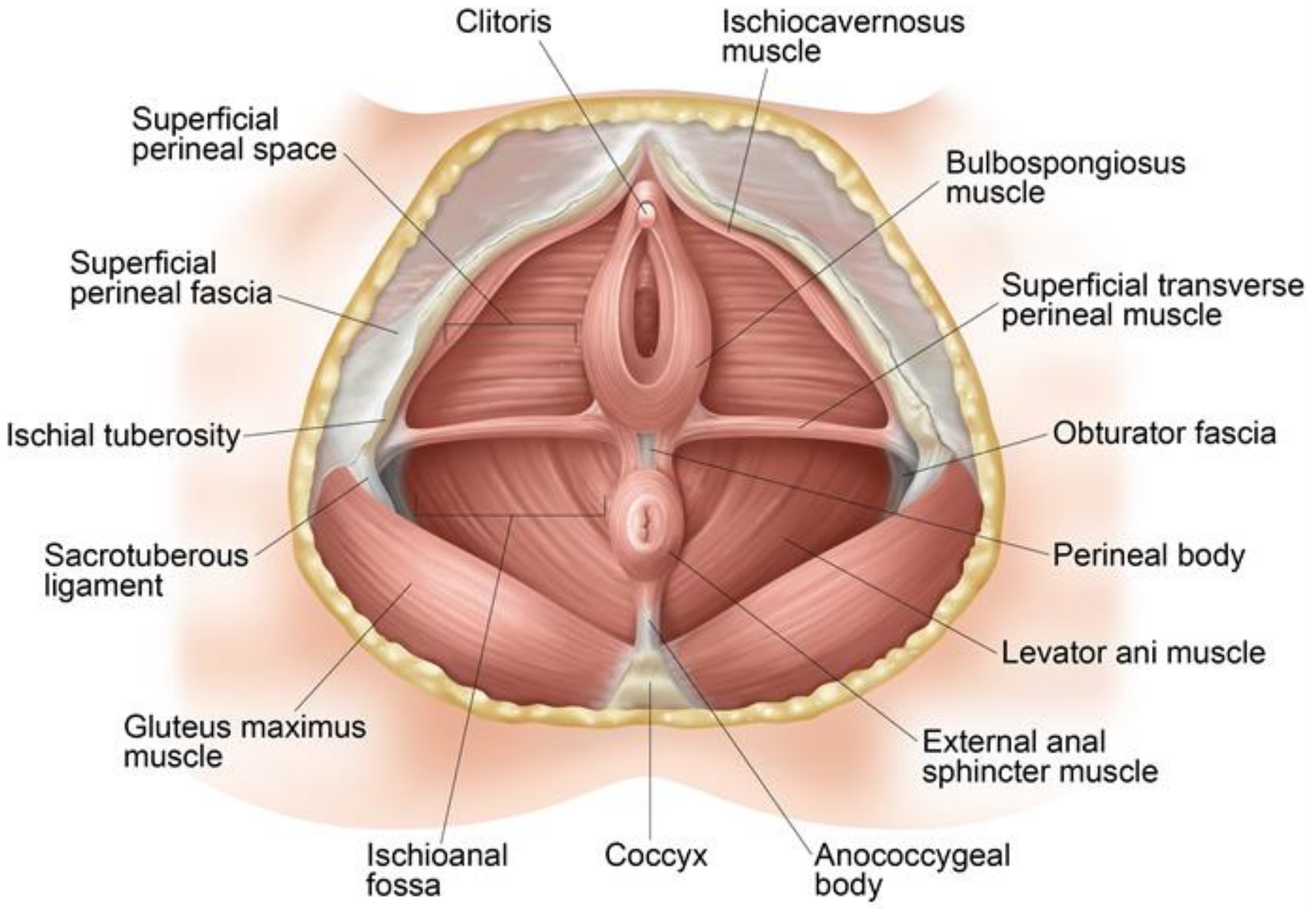

©UWorld

The **perineal body** is essential to the integrity of the pelvic floor. This **tendinous center point of the perineum** separates the urogenital and anal triangles. It blends anteriorly with the perineal membrane and superiorly with the rectovesical or rectovaginal septum. The following structures are anchored to the perineal body:

The **perineal body** is essential to the integrity of the pelvic floor. This **tendinous center point of the perineum** separates the urogenital and anal triangles. It blends anteriorly with the perineal membrane and superiorly with the rectovesical or rectovaginal septum. The following structures are anchored to the perineal body:

- Bulbospongiosus muscle
- External anal sphincter muscle
- Superficial and deep transverse perineal muscles
- Fibers from the external urethral sphincter, levator ani, and muscular coat of the rectum

Episiotomies are used to enlarge the vaginal outlet to facilitate delivery and reduce the risk of severe perineal laceration. A **midline episiotomy** is a vertical incision from the posterior vaginal opening to the perineal body. It transects the vaginal lining and the submucosal tissue but not the external anal sphincter or the rectal mucosa **(Choice E)**. Improper repair of a midline episiotomy may result in pelvic organ prolapse or dyspareunia.

(Choice A) The external anal sphincter is part of the anal triangle. It arises from the coccyx and anococcygeal ligament and inserts into the perineal body. Women with severe perineal lacerations are at risk for fecal incontinence due to anal sphincter damage.

(Choice B) The ischiocavernosus muscle is part of the urogenital triangle. It arises from the inner surface of the ischial tuberosities and the ischiopubic rami and inserts into the corpus cavernosum. When the clitoris is stimulated, the ischiocavernosus muscle forces blood into the clitoris.

(Choice C) The levator ani muscle (part of the anal triangle) supports the pelvic floor and can be strengthened by Kegel exercises. This muscle is often stretched, pushed aside, and torn by fetal crowning and delivery. It is not usually incised during an episiotomy.

(Choice F) The transverse perineal muscle is part of the superficial perineal space (urogenital triangle). It arises from the ischial rami and tuberosities and inserts into the perineal body. This muscle is cut during a mediolateral episiotomy.

Educational objective:
The perineal body is a fibromuscular tissue between the urogenital and anal triangle. A midline episiotomy is a vertical incision from the posterior vaginal opening to the perineal body. It transects the vaginal submucosal tissue but not the external anal sphincter or the rectal mucosa.

References

Episiotomies are used to enlarge the vaginal outlet to facilitate delivery and reduce the risk of severe perineal laceration. A **midline episiotomy** is a vertical incision from the posterior vaginal opening to the perineal body. It transects the vaginal lining and the submucosal tissue but not the external anal sphincter or the rectal mucosa **(Choice E)**. Improper repair of a midline episiotomy may result in pelvic organ prolapse or dyspareunia.

(Choice A) The external anal sphincter is part of the anal triangle. It arises from the coccyx and anococcygeal ligament and inserts into the perineal body. Women with severe perineal lacerations are at risk for fecal incontinence due to anal sphincter damage.

(Choice B) The ischiocavernosus muscle is part of the urogenital triangle. It arises from the inner surface of the ischial tuberosities and the ischiopubic rami and inserts into the corpus cavernosum. When the clitoris is stimulated, the ischiocavernosus muscle forces blood into the clitoris.

(Choice C) The levator ani muscle (part of the anal triangle) supports the pelvic floor and can be strengthened by Kegel exercises. This muscle is often stretched, pushed aside, and torn by fetal crowning and delivery. It is not usually incised during an episiotomy.

(Choice F) The transverse perineal muscle is part of the superficial perineal space (urogenital triangle). It arises from the ischial rami and tuberosities and inserts into the perineal body. This muscle is cut during a mediolateral episiotomy.

Educational objective:
The perineal body is a fibromuscular tissue between the urogenital and anal triangle. A midline episiotomy is a vertical incision from the posterior vaginal opening to the perineal body. It transects the vaginal submucosal tissue but not the external anal sphincter or the rectal mucosa.

References

- Continuous and interrupted suturing techniques for repair of episiotomy or second-degree tears.
- Review article: Risk factors for severe perineal lacerations during childbirth.

Anatomy	Female Reproductive System & Breast	Perineal lacerations
Subject	System	Topic

Copyright © UWorld. All rights reserved.

A 29-year-old nulliparous woman comes to the emergency department with right-sided pelvic pain. The pain is sharp and came on suddenly while she was shoveling snow this morning. It is accompanied by nausea and is worse with movement. The patient's last menstrual period was 2 weeks ago. Her temperature is 37.8 C (100 F), blood pressure is 100/60 mm Hg, and pulse is 92/min. Pelvic ultrasound reveals a normal-sized uterus and left ovary, and a right adnexal mass measuring 6 cm with no blood flow to the ovary. Urine β-hCG is negative. The patient's condition most likely involves pathology in which of the following structures?

A. Broad ligament

B. Infundibulopelvic ligament

C. Mesosalpinx

D. Round ligament

E. Uterosacral ligament

Submit

A 29-year-old nulliparous woman comes to the emergency department with right-sided pelvic pain. The pain is sharp and came on suddenly while she was shoveling snow this morning. It is accompanied by nausea and is worse with movement. The patient's last menstrual period was 2 weeks ago. Her temperature is 37.8 C (100 F), blood pressure is 100/60 mm Hg, and pulse is 92/min. Pelvic ultrasound reveals a normal-sized uterus and left ovary, and a right adnexal mass measuring 6 cm with no blood flow to the ovary. Urine β-hCG is negative. The patient's condition most likely involves pathology in which of the following structures?

- A. Broad ligament (14%)
- ✓ B. Infundibulopelvic ligament (45%)
- C. Mesosalpinx (14%)
- D. Round ligament (22%)
- E. Uterosacral ligament (1%)

Omitted
Correct answer
B

45%
Answered correctly

02 secs
Time Spent

02/26/2020
Last Updated

Explanation

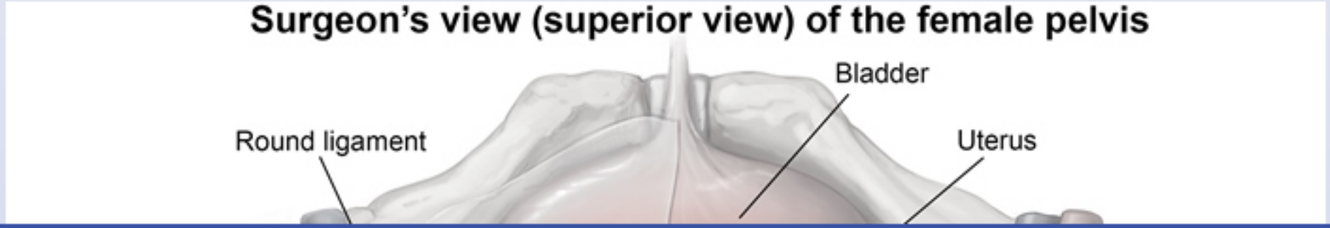

Surgeon's view (superior view) of the female pelvis

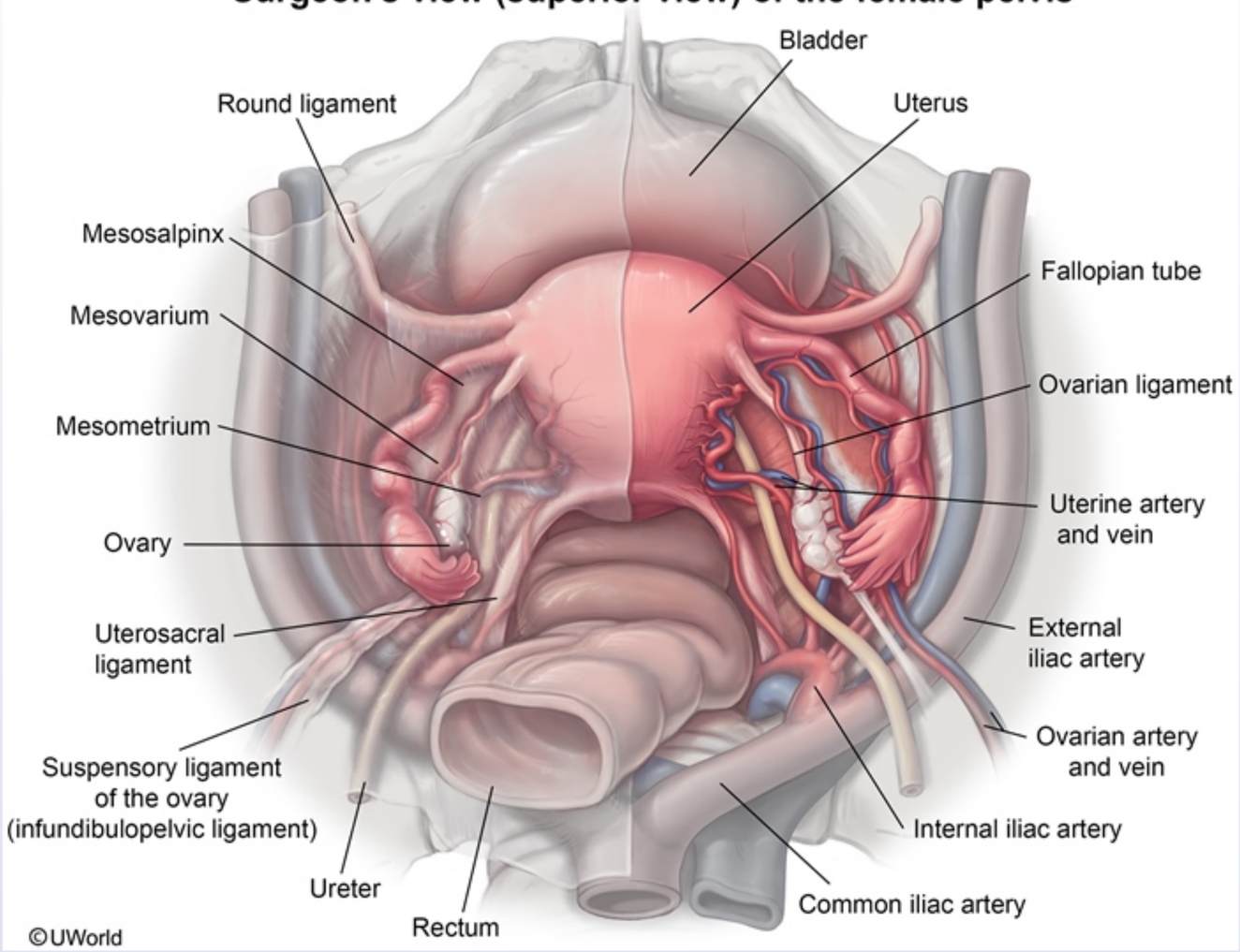

The ovary is suspended posterolaterally to the uterus by the utero-ovarian ligament and receives its blood supply through the vessels that traverse the **infundibulopelvic (IP) ligament (eg, suspensory ligament of the ovary)**. The IP ligament also houses the ovarian nerve plexus. Rotation of the ovary around the IP ligament results in **ovarian torsion**.

The ovary is suspended posterolaterally to the uterus by the utero-ovarian ligament and receives its blood supply through the vessels that traverse the **infundibulopelvic (IP) ligament (eg, suspensory ligament of the ovary)**. The IP ligament also houses the ovarian nerve plexus. Rotation of the ovary around the IP ligament results in **ovarian torsion**.

The main risk factor for torsion is the presence of a large ovarian mass (eg, cyst, neoplasm). The weight of the mass causes the ovary to **twist** and **occlude the ovarian vessels and nerves**. When blood flow to the ovary is completely blocked, the torsed ovary becomes edematous and ischemic. A patient with ovarian torsion will typically present with sudden-onset **unilateral pelvic pain** and nausea and sometimes vomiting and fever. Pelvic ultrasound is the first-line diagnostic test and may show decreased or no blood flow to the ovary.

(Choices A and C) The mesosalpinx is the portion of the broad ligament that connects the fallopian tubes to the pelvic sidewall. The broad ligament is a wide sheet of peritoneal tissue that encapsulates the reproductive organs anteriorly and posteriorly and attaches the uterus to the pelvic sidewalls bilaterally, making torsion of the ovary around the broad ligament (including mesosalpinx) anatomically impossible.

(Choice D) The round ligament maintains the anteflexion of the uterus. It runs from the lower aspect of the uterus through the inguinal ring to the labia majora and is not connected to the ovaries. During pregnancy, a woman may experience intermittent sharp pain due to irritation from sudden movements of the stretching round ligament.

(Choice E) The uterosacral ligaments connect the posterior aspect of the uterus to the anterior portion of the sacrum. These ligaments hold the uterus in an anteverted or retroverted position; loss of this support contributes to uterine prolapse into the vagina. They are not involved in the positioning or vascular supply of the ovaries.

Educational objective:
Ovarian torsion typically involves twisting of the infundibulopelvic ligament, often due to the weight of a large adnexal mass. The resulting occlusion of the blood and nerve supply to the ovary results in severe, acute pelvic pain and ovarian ischemia.

References

- Clinical risk factors for ovarian torsion.

Anatomy	Female Reproductive System & Breast	Ovarian Torsion
Subject	System	Topic

1
2
3
4
5
6
7
8
9
10
11
12
13
14
15
16
17
18
19
20
21
22

The ovary is suspended posterolaterally to the uterus by the utero-ovarian ligament and receives its blood supply through the vessels that traverse

Exhibit Display

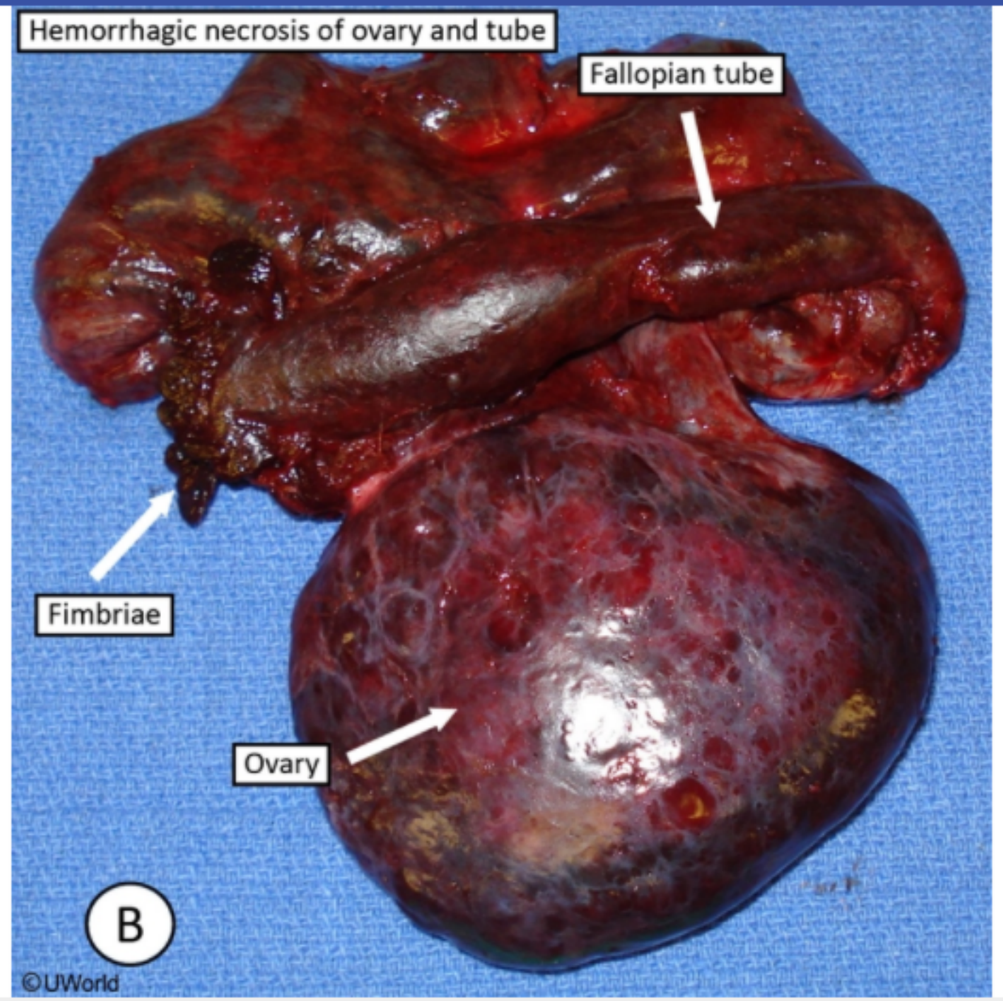

Zoom In | Zoom Out | Reset | Add To New Card | Existing Card

A 6-month-old boy is brought to the urology clinic for follow-up of an undescended right testicle discovered during evaluation in the newborn nursery. Physical examination shows absence of a palpable right testis in the scrotal sac. However, a round mass is palpated superior to the scrotum in the inguinal canal. Orchiopexy, the placement and fixation of the testis in the scrotum, is recommended to the family. During this patient's procedure, the malpositioned testis will most likely be pulled through a physiologic opening in which of the following structures?

A. Conjoint tendon

B. External oblique muscle aponeurosis

C. Femoral ring

D. Internal oblique muscle aponeurosis

E. Rectus muscle sheath

Submit

A 6-month-old boy is brought to the urology clinic for follow-up of an undescended right testicle discovered during evaluation in the newborn nursery. Physical examination shows absence of a palpable right testis in the scrotal sac. However, a round mass is palpated superior to the scrotum in the inguinal canal. Orchiopexy, the placement and fixation of the testis in the scrotum, is recommended to the family. During this patient's procedure, the malpositioned testis will most likely be pulled through a physiologic opening in which of the following structures?

- A. Conjoint tendon (5%)
- ✓ B. External oblique muscle aponeurosis (38%)
- C. Femoral ring (16%)
- D. Internal oblique muscle aponeurosis (32%)
- E. Rectus muscle sheath (7%)

Omitted
Correct answer
B

38%
Answered correctly

02 secs
Time Spent

02/19/2020
Last Updated

Explanation

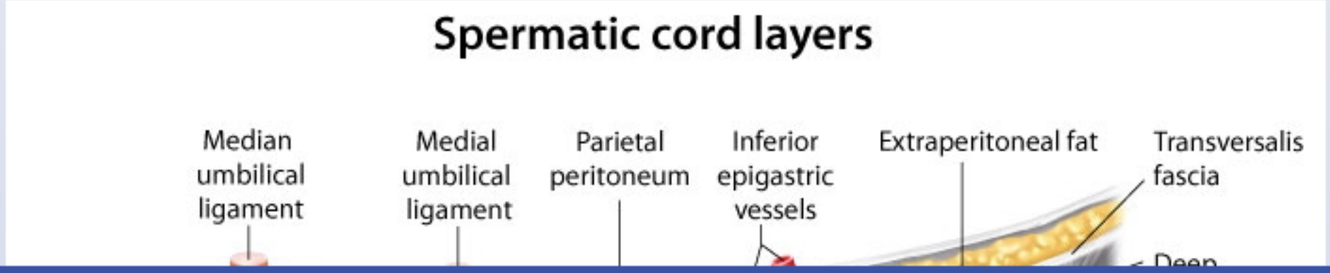

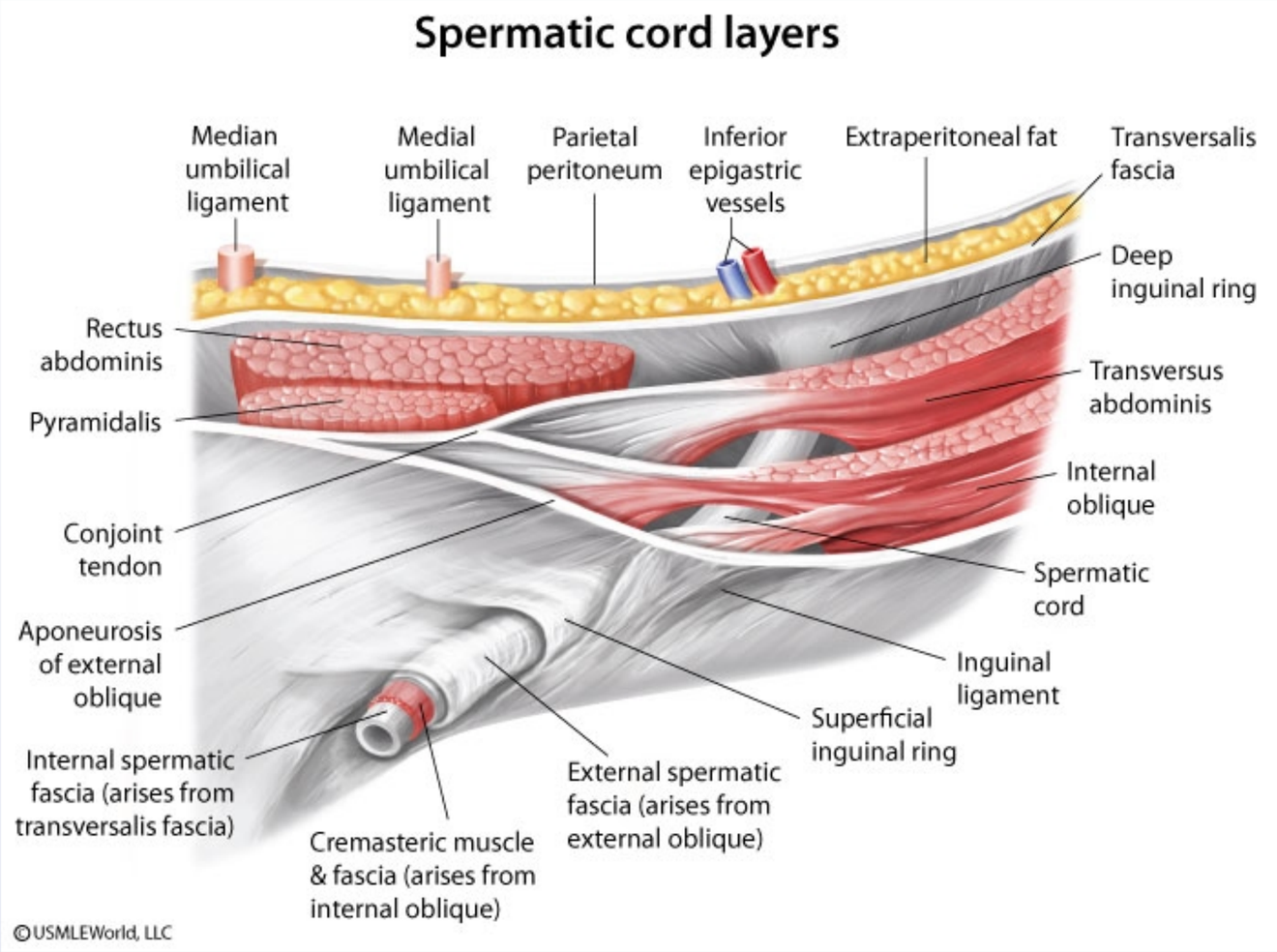

Testicles develop in the fetal abdomen during organogenesis. Between 8 weeks and full term, each testis descends from the abdomen into the inguinal canal through the deep inguinal ring, which is an opening in the transversalis fascia bounded laterally by the transversus abdominis muscle and medially by the inferior epigastric vessels. Each testis then passes anteromedially through the canal and enters the scrotum via the **superficial inguinal ring**, which is a physiologic opening in the **external oblique muscle aponeurosis** above the pubic tubercle.

©USMLEWorld, LLC

Testicles develop in the fetal abdomen during organogenesis. Between 8 weeks and full term, each testis descends from the abdomen into the inguinal canal through the deep inguinal ring, which is an opening in the transversalis fascia bounded laterally by the transversus abdominis muscle and medially by the inferior epigastric vessels. Each testis then passes anteromedially through the canal and enters the scrotum via the **superficial inguinal ring**, which is a physiologic opening in the **external oblique muscle aponeurosis** above the pubic tubercle.

Cryptorchidism is the failure of one or both testes to descend to the scrotum before birth, which occurs more commonly in preterm neonates. It is associated with a significantly increased risk of **testicular cancer** and **infertility**. A testis that is palpable in the inguinal canal typically descends spontaneously by age 6 months. Testes that have not descended by this point are unlikely to do so and require surgical intervention (ie, **orchiopexy**).

In this case, the patient's undescended testicle is **lodged within the inguinal canal** and must be mobilized through the superficial inguinal ring and stitched into place in the scrotum.

(Choice A) The conjoint tendon is the common tendon of the transversus abdominis and internal oblique muscles. It forms part of the posterior wall of the inguinal canal.

(Choice C) The femoral ring is a physiologic opening between the abdominal cavity and the femoral canal. It transmits lymphatic vessels but not the spermatic cord.

(Choice D) The internal oblique muscle aponeurosis contributes to the formation of the conjoint tendon and rectus muscle sheath. In addition, the cremaster muscle originates from the internal oblique muscle itself.

(Choice E) The rectus muscle sheath is formed by the confluence of the aponeuroses of the external and internal oblique muscles and the transversus abdominis muscle.

Educational objective:
The superficial and deep inguinal rings are physiologic openings in the external abdominal oblique aponeurosis and the transversalis fascia, respectively. Surgical repair of an undescended testicle lodged in the inguinal canal involves moving the testis through the superficial inguinal ring and fixing it in the scrotum (ie, orchiopexy).

©USMLEWorld, LLC

Exhibit Display

Groin hernias

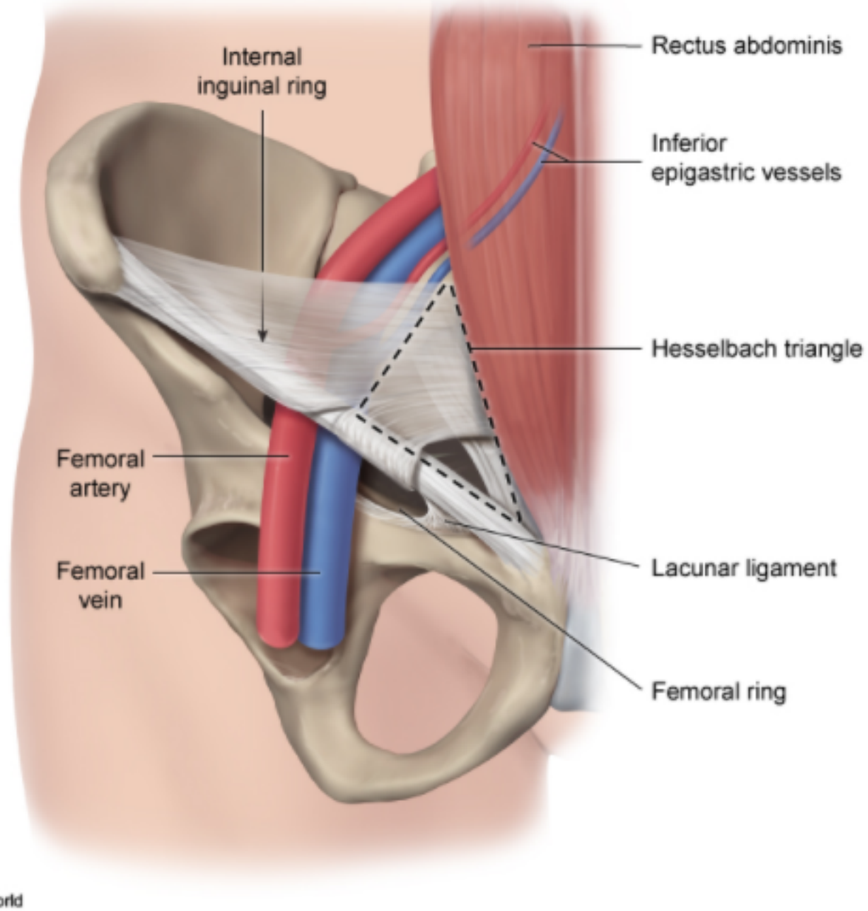

©UWorld

Zoom In | Zoom Out | Reset | Add To New Card | Existing Card

A 52-year-old postmenopausal woman comes to the office due to leakage of a few urine drops with coughing and sneezing. She has no dysuria, urgency, or changes in urinary frequency. The patient has had 3 spontaneous vaginal deliveries. Physical examination is notable for a mild cystocele. The patient is advised to perform exercises to strengthen her pelvic floor as part of treatment for her symptoms. Which of the following structures is the most likely target of the exercise?

A. Bulbospongiosus muscle
B. Detrusor muscle
C. External urethral sphincter
D. Internal urethral sphincter
E. Levator ani muscle
F. Uterosacral ligament

Submit

A 52-year-old postmenopausal woman comes to the office due to leakage of a few urine drops with coughing and sneezing. She has no dysuria, urgency, or changes in urinary frequency. The patient has had 3 spontaneous vaginal deliveries. Physical examination is notable for a mild cystocele. The patient is advised to perform exercises to strengthen her pelvic floor as part of treatment for her symptoms. Which of the following structures is the most likely target of the exercise?

- A. Bulbospongiosus muscle (4%)
- B. Detrusor muscle (8%)
- C. External urethral sphincter (21%)
- D. Internal urethral sphincter (5%)
- ✓ E. Levator ani muscle (59%)
- F. Uterosacral ligament (1%)

Omitted
Correct answer
E

59%
Answered correctly

02 secs
Time Spent

04/05/2020
Last Updated

Explanation

Female pelvic floor muscles

Explanation

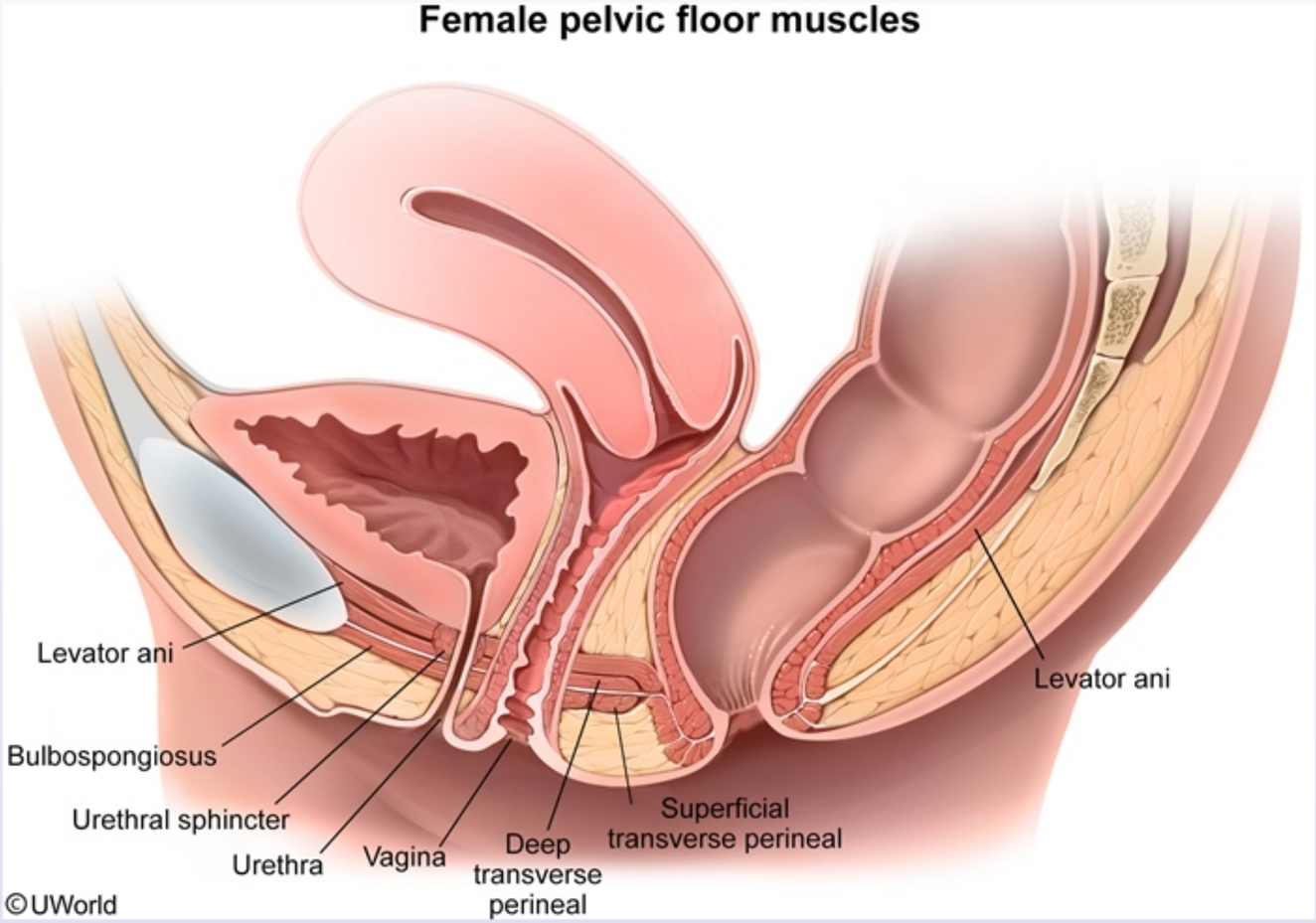

Women who are obese or have had prolonged second stage of labor, multiple vaginal deliveries, or previous pelvic surgery (ie, hysterectomy) are at increased risk for **pelvic floor injury**. The pelvic floor is composed of the levator ani muscles and forms a U-shaped sling around the pelvic viscera. The **levator ani muscles** (ie, iliococcygeus, pubococcygeus, puborectalis) hold the bladder and the urethra in the appropriate anatomic position. Injury to these muscles results in **urethral hypermobility** and/or pelvic organ prolapse (eg, cystocele).

Women who are obese or have had prolonged second stage of labor, multiple vaginal deliveries, or previous pelvic surgery (ie, hysterectomy) are at increased risk for **pelvic floor injury**. The pelvic floor is composed of the levator ani muscles and forms a U-shaped sling around the pelvic viscera. The **levator ani muscles** (ie, iliococcygeus, pubococcygeus, puborectalis) hold the bladder and the urethra in the appropriate anatomic position. Injury to these muscles results in **urethral hypermobility** and/or pelvic organ prolapse (eg, cystocele).

Urethral hypermobility results in incomplete closure of the urethra and bladder neck against the anterior vaginal wall, which leads to **stress urinary incontinence (SUI)**. Patients with SUI have **involuntary urine loss** with **increased intraabdominal pressure** (eg, coughing, laughing, straining from constipation) and no bladder contraction.

First-line management of SUI is through lifestyle modifications, such as increased dietary fiber to prevent straining. Urethral support can be strengthened through pelvic floor exercises (eg, **Kegel exercises**) involving squeezing and releasing the levator ani muscles a few times each day.

(Choice A) The bulbospongiosus muscle is part of the superficial urogenital triangle of the perineum. It compresses the vestibular bulb and constricts the vaginal orifice.

(Choice B) The detrusor muscle is a smooth muscle lining the bladder wall that contracts to release urine from the bladder. Detrusor overactivity results in urge incontinence. Impairment of detrusor contractions from a sacral lesion or autonomic neuropathies will result in overflow incontinence.

(Choice C) The external urethral sphincter is a skeletal muscle located at the distal end of the urethra and innervated by the pudendal nerve. Voluntary constriction of the external urethral sphincter maintains continence, and prolonged labor can damage this muscle, resulting in urinary incontinence.

(Choice D) The internal urethral sphincter is a smooth muscle at the proximal junction of the bladder and the urethra. The sympathetic nervous system controls this sphincter to constrict and prevent urine leakage.

(Choice F) The uterosacral ligaments run along the lateral pelvic wall and anchor the uterus and vaginal apex by attaching to the sacrum. Weakening of these ligaments contributes to uterine and vaginal apical prolapse.

Educational objective:
Stress urinary incontinence is defined as involuntary urine loss with increased intraabdominal pressure. Pelvic floor strengthening (eg, Kegel exercises) targets the levator ani to improve support around the urethra and bladder.

day.

(Choice A) The bulbospongiosus muscle is part of the superficial urogenital triangle of the perineum. It compresses the vestibular bulb and constricts the vaginal orifice.

(Choice B) The detrusor muscle is a smooth muscle lining the bladder wall that contracts to release urine from the bladder. Detrusor overactivity results in urge incontinence. Impairment of detrusor contractions from a sacral lesion or autonomic neuropathies will result in overflow incontinence.

(Choice C) The external urethral sphincter is a skeletal muscle located at the distal end of the urethra and innervated by the pudendal nerve. Voluntary constriction of the external urethral sphincter maintains continence, and prolonged labor can damage this muscle, resulting in urinary incontinence.

(Choice D) The internal urethral sphincter is a smooth muscle at the proximal junction of the bladder and the urethra. The sympathetic nervous system controls this sphincter to constrict and prevent urine leakage.

(Choice F) The uterosacral ligaments run along the lateral pelvic wall and anchor the uterus and vaginal apex by attaching to the sacrum. Weakening of these ligaments contributes to uterine and vaginal apical prolapse.

Educational objective:
Stress urinary incontinence is defined as involuntary urine loss with increased intraabdominal pressure. Pelvic floor strengthening (eg, Kegel exercises) targets the levator ani to improve support around the urethra and bladder.

References

- Conservative Management of Urinary Incontinence in Women.
- Role of pelvic floor in lower urinary tract function.

Anatomy	Female Reproductive System & Breast	Urinary incontinence
Subject	System	Topic

Copyright © UWorld. All rights reserved.

1
2
3
4
5
6
7
8
9
10
11
12
13
14
15
16
17
18
19
20
21
22

Exhibit Display

Cystocele, prolapse of anterior vaginal wall

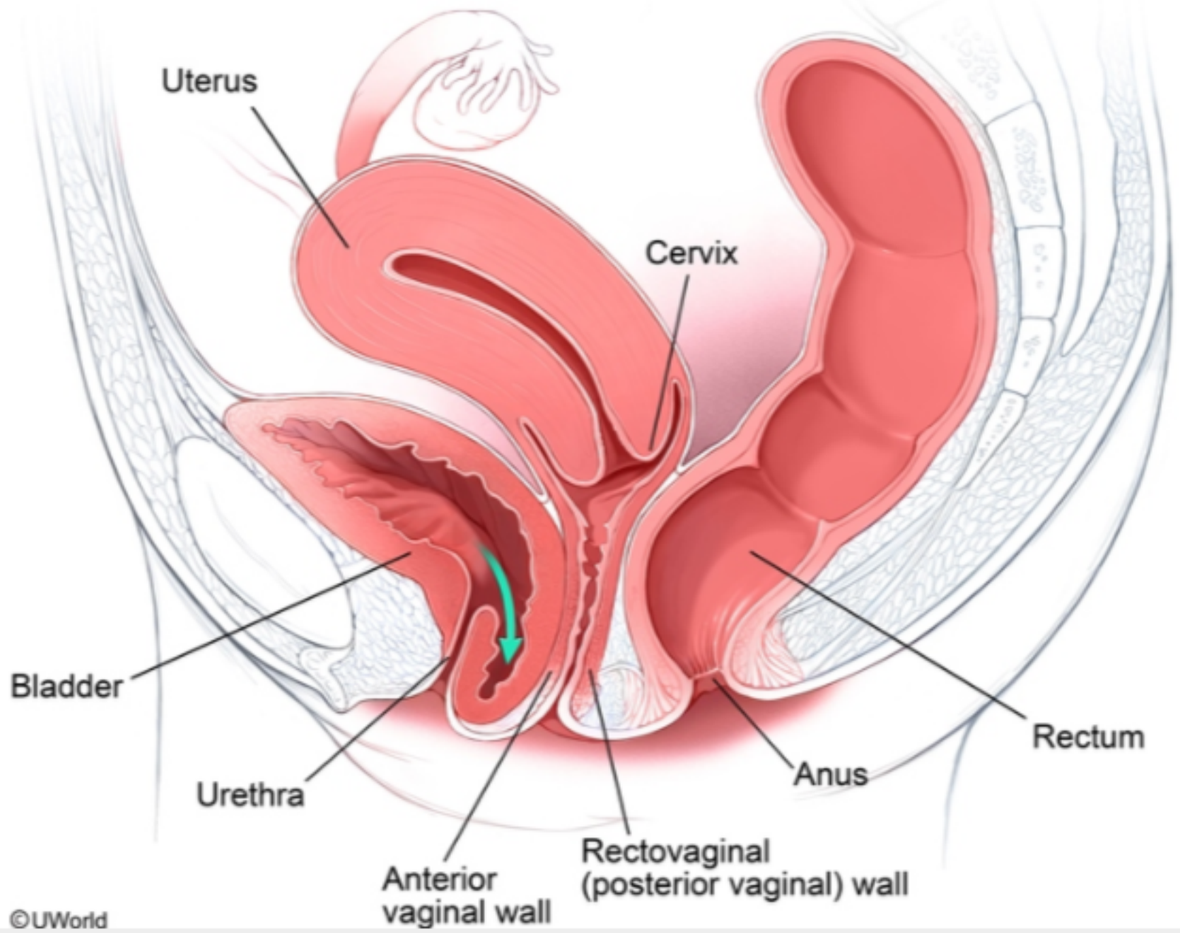

Zoom In | Zoom Out | Reset | Add To New Card | Existing Card

results in urge incontinence. Impairment of detrusor contractions from a sacral lesion or autonomic neuropathies will result in overflow

1
2
3
4
5
6
7
8
9
10
11
12
13
14
15
16
17
18
19
20
21
22

First-line management of SUI is through lifestyle modifications, such as increased dietary fiber to prevent straining. Urethral support can be

Exhibit Display

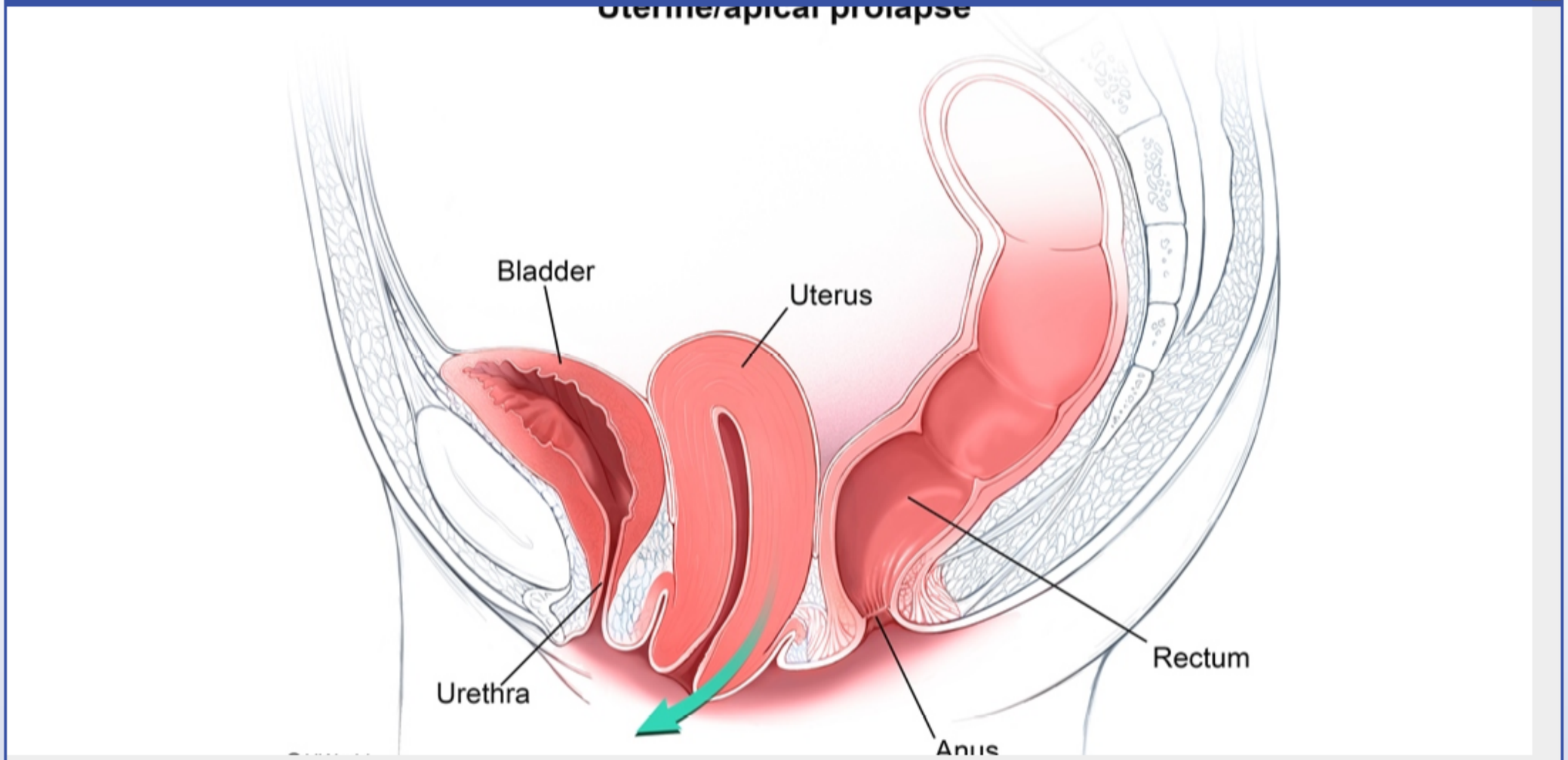

Zoom In | Zoom Out | Reset | Add To New Card | Existing Card

A 21-year-old previously healthy man comes to the emergency department with acute onset of severe left scrotal pain and nausea. The pain started after he returned home from the gym following an intense workout. He denies any trauma, fever, or dysuria. Examination shows a swollen and tender left testis that lies higher than the right testis. Doppler ultrasound shows decreased arterial blood flow in the left spermatic cord entering the testis. Which of the following is the likely origin of the artery involved in this patient's condition?

- A. Abdominal aorta
- B. External iliac artery
- C. Internal iliac artery
- D. Internal pudendal artery
- E. Obturator artery
- F. Renal artery

Submit

A 21-year-old previously healthy man comes to the emergency department with acute onset of severe left scrotal pain and nausea. The pain started after he returned home from the gym following an intense workout. He denies any trauma, fever, or dysuria. Examination shows a swollen and tender left testis that lies higher than the right testis. Doppler ultrasound shows decreased arterial blood flow in the left spermatic cord entering the testis. Which of the following is the likely origin of the artery involved in this patient's condition?

- ✓ A. Abdominal aorta (47%)
- B. External iliac artery (2%)
- C. Internal iliac artery (16%)
- D. Internal pudendal artery (6%)
- E. Obturator artery (0%)
- F. Renal artery (27%)

Omitted
Correct answer
A

47%
Answered correctly

02 secs
Time Spent

04/21/2020
Last Updated

Explanation

Gonadal vasculature

Gonadal vasculature

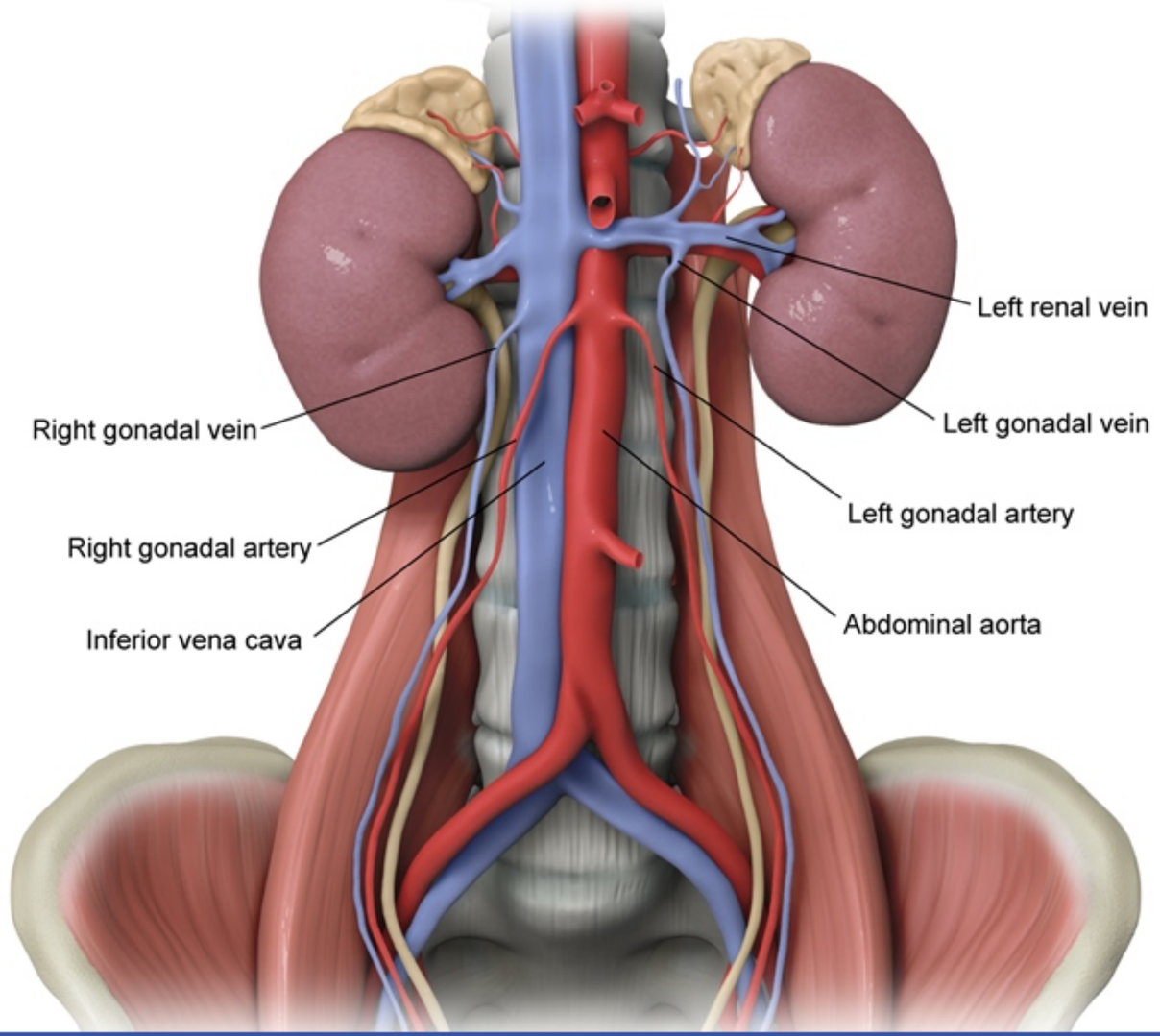

©UWorld

The **gonadal arteries** arise from the **abdominal aorta** slightly below the renal arteries. Each gonadal artery courses obliquely downward and laterally within the retroperitoneal space near the psoas major muscle. After crossing anteriorly over the ureter, the gonadal arteries run parallel to the external iliac vessels and eventually traverse the inguinal canal to supply the testes via the spermatic cord in males.

This patient most likely has testicular torsion, which is usually due to inadequate fixation of the lower pole of the testis to the tunica vaginalis. Testicular torsion is caused by twisting of the spermatic cord, resulting in compression of the pampiniform plexus of the testicular vein and reduced venous outflow. Arterial blood flow in the testicular arteries is initially preserved or slightly decreased, leading to engorgement and eventual **hemorrhagic infarction**. Torsion is characterized by **acute, severe pain** with nausea/vomiting, an asymmetrically **high-riding testis**, and absent cremasteric reflex (elevation of testis while pinching the skin in upper thigh).

(Choices B and C) The external and internal iliac arteries arise from the common iliac artery. The external iliac artery travels underneath the inguinal ligament and becomes the femoral artery, which supplies the lower extremity. The internal iliac artery provides blood supply to the pelvic wall/viscera, buttock, female reproductive organs, bladder, and medial thigh.

(Choice D) The internal pudendal artery is a branch of the internal iliac artery and provides blood supply to the anal canal, scrotum, and penis. However, it does not provide blood supply to the testis.

(Choice E) The obturator artery arises from the internal iliac artery and provides blood supply to the pelvis, bladder, and parts of the femoral head and medial thigh muscles.

(Choice F) The renal artery provides blood supply to the kidney. Branches of the renal artery supply the ureter but do not travel to the testis. Unlike the gonadal arteries, the gonadal veins arise from different structures. The right gonadal vein drains directly into the inferior vena cava while the left gonadal vein drains into the left renal vein.

Educational objective:
Testicular torsion is due to twisting of the testis around the spermatic cord (containing the gonadal artery), which can eventually lead to ischemia. The gonadal arteries arise from the abdominal aorta. The right gonadal vein drains directly into the inferior vena cava while the left gonadal vein drains into the left renal vein.

References

- Testicular torsion: diagnosis, evaluation, and management.

©UWorld

Exhibit Display

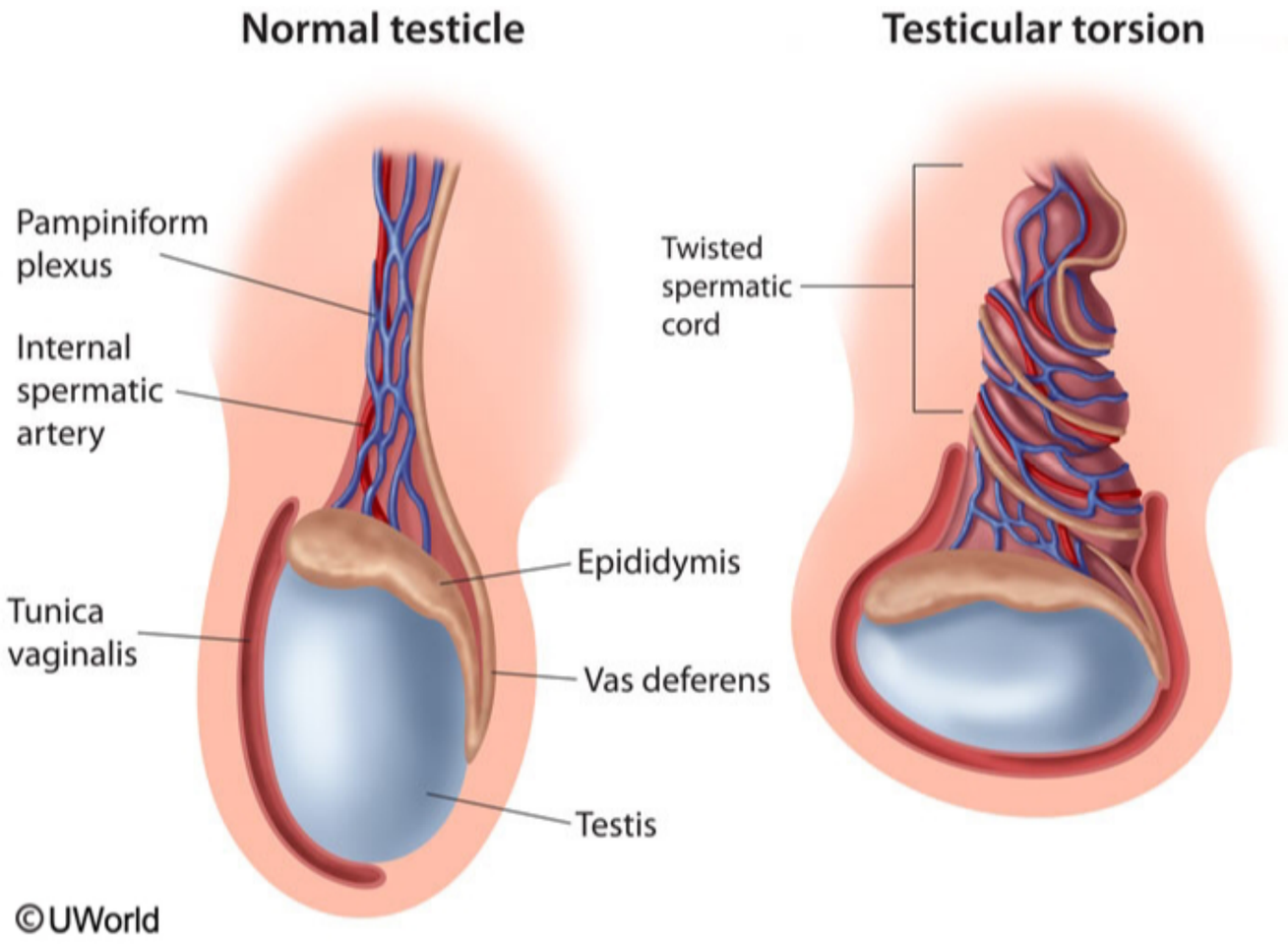

Zoom In | Zoom Out | Reset | Add To New Card | Existing Card

- Testicular torsion: diagnosis, evaluation, and management.

A 16-year-old girl comes to the office due to pelvic and crampy lower abdominal pain that seems to recur at the beginning of each month and resolves after a day or two. She thinks the pain began approximately 6 months ago, and it is worsening significantly each month. The patient has never had a menstrual period. She and her boyfriend have not had any form of sexual intercourse, including digital, oral, vaginal, or anal. The patient's weight, height, and BMI are average for age and sex, and she has fully developed secondary sexual characteristics. Examination reveals a palpable mass anterior to the rectum. Serum β-hCG is negative. Which of the following is the most likely diagnosis in this patient?

A. Androgen insensitivity syndrome
B. Asherman syndrome
C. Endometriosis
D. Imperforate hymen
E. Kallmann syndrome
F. Turner syndrome

Submit

A 16-year-old girl comes to the office due to pelvic and crampy lower abdominal pain that seems to recur at the beginning of each month and resolves after a day or two. She thinks the pain began approximately 6 months ago, and it is worsening significantly each month. The patient has never had a menstrual period. She and her boyfriend have not had any form of sexual intercourse, including digital, oral, vaginal, or anal. The patient's weight, height, and BMI are average for age and sex, and she has fully developed secondary sexual characteristics. Examination reveals a palpable mass anterior to the rectum. Serum β-hCG is negative. Which of the following is the most likely diagnosis in this patient?

- A. Androgen insensitivity syndrome (8%)
- B. Asherman syndrome (5%)
- C. Endometriosis (20%)
- ✓ D. Imperforate hymen (61%)
- E. Kallmann syndrome (3%)
- F. Turner syndrome (1%)

Omitted
Correct answer
D

61%
Answered correctly

02 secs
Time Spent

04/02/2020
Last Updated

Explanation

Hematocolpos

1
2
3
4
5
6
7
8
9
10
11
12
13
14
15
16
17
18
19
20
21
22

Hematocolpos

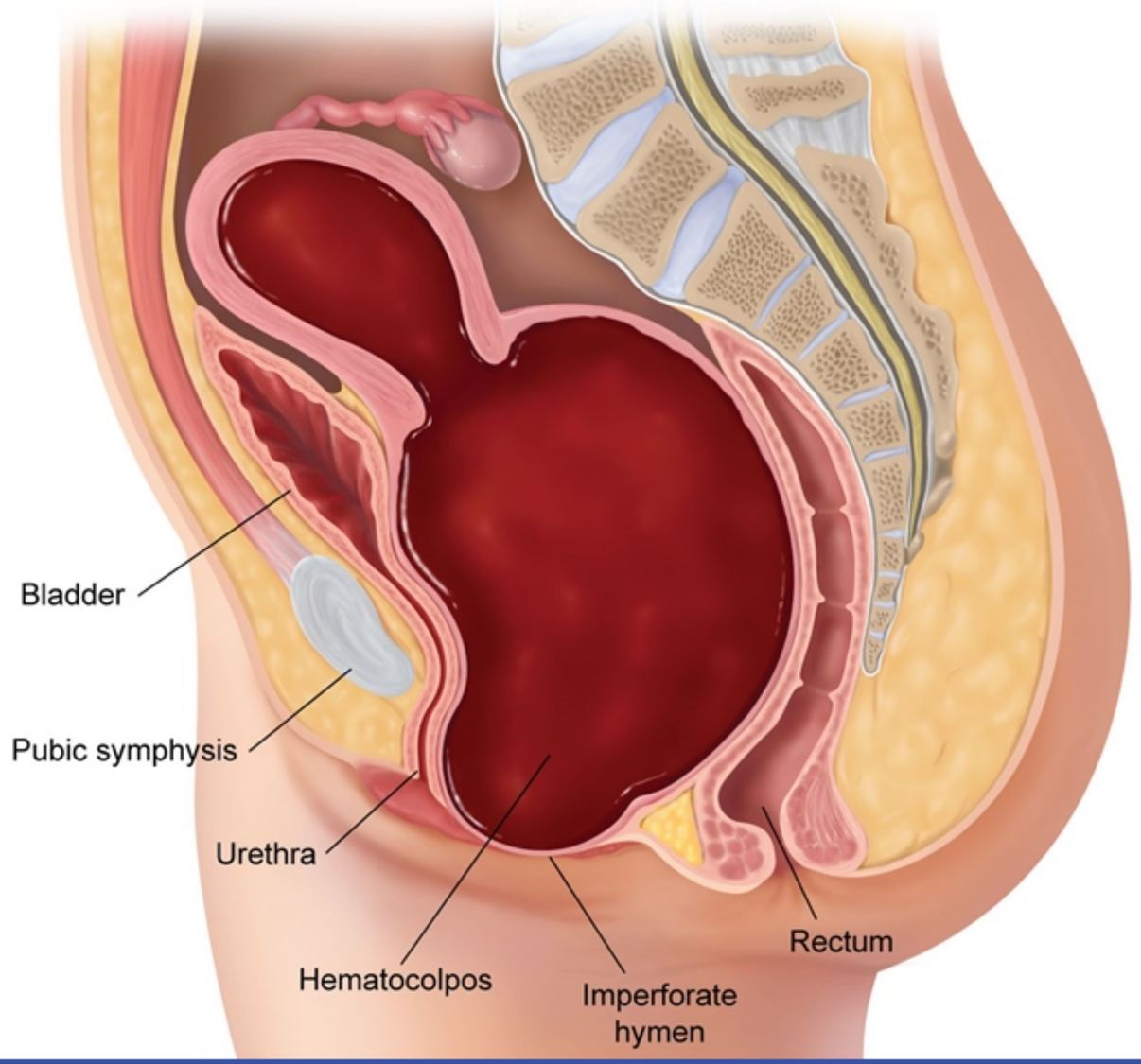

©UWorld

An **imperforate hymen** is an obstructive lesion caused by incomplete degeneration of the central portion of the fibrous tissue band connecting the walls of the vagina. At birth, vaginal secretions stimulated by the mother's estrogen can cause mucocolpos (accumulation of mucus in the vaginal canal), which may manifest as a bulging introitus. If the condition remains undiagnosed, the mucus is reabsorbed and the child will be asymptomatic until menarche. The patient may then present with **primary amenorrhea** and normal secondary sexual characteristics with **cyclic** abdominal or **pelvic pain** due to accumulation of menstrual blood in the vagina and uterus (eg, **hematocolpos**). The pressure from the resulting collection of blood can also cause back pain and difficulties with defecation. **Secondary sexual development** is normal as the patient has no chromosomal or hormonal abnormalities. Examination may show a vaginal bulge and/or mass palpated anterior to the rectum.

(Choice A) Patients with androgen insensitivity syndrome are genetically male but have a female phenotype due to resistance to testosterone. In adolescence, breast development results from peripheral conversion of testosterone to estrogen, but axillary and pubic hair is absent. Primary amenorrhea occurs due to a complete absence of Müllerian structures.

(Choice B) Asherman syndrome causes secondary amenorrhea through obstruction from scarring of the uterine cavity. This is typically a sequela of uterine infection (eg, postpartum endometritis) or procedures (eg, dilation and curettage).

(Choice C) Endometriosis is the presence of endometrial glands and stroma outside the uterus. It may cause severe dysmenorrhea (not amenorrhea) with lower abdominal cramps that begin 1-2 days before menses. A common site of endometrial implants is the pouch of Douglas, which presents as painful defecation, dyspareunia, and palpable nodularity on rectovaginal examination.

(Choice E) Kallmann syndrome occurs due to impaired synthesis of gonadotropin-releasing hormone by the hypothalamus. The condition presents with primary amenorrhea, absent secondary sexual characteristics, and an olfactory sensory defect.

(Choice F) Turner syndrome (45,XO) is the most common cause of primary amenorrhea. Affected individuals have short stature, webbed neck, shielded chest, and fibrotic ovaries, and do not develop secondary sexual characteristics.

Educational objective:
Imperforate hymen is caused by incomplete degeneration of the central portion of the fibrous tissue band connecting the walls of the vagina. Adolescent patients typically present with primary amenorrhea, normal secondary sexual characteristics, and cyclic abdominal or pelvic pain due to accumulation of menstrual blood in the vagina and uterus (eg, hematocolpos).

References

©UWorld

1
2
3
4
5
6
7
8
9
10
11
12
13
14
15
16
17
18
19
20
21
22

Exhibit Display

Imperforate hymen

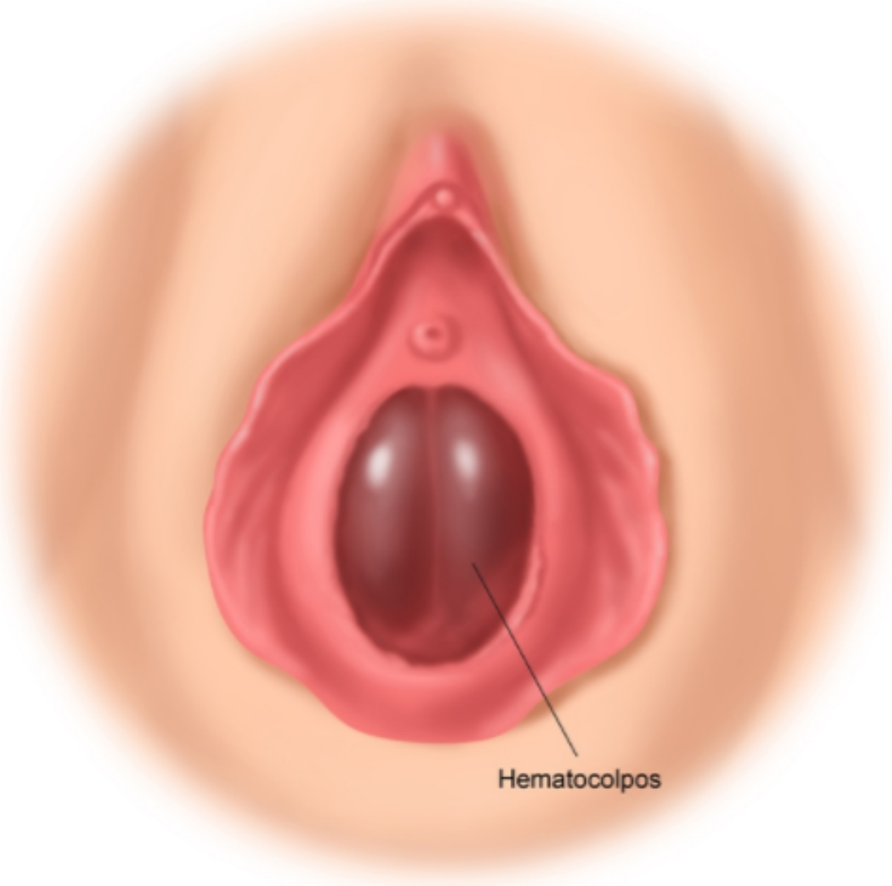

©UWorld

Zoom In | Zoom Out | Reset | Add To New Card | Existing Card

References

©UWorld

Exhibit Display

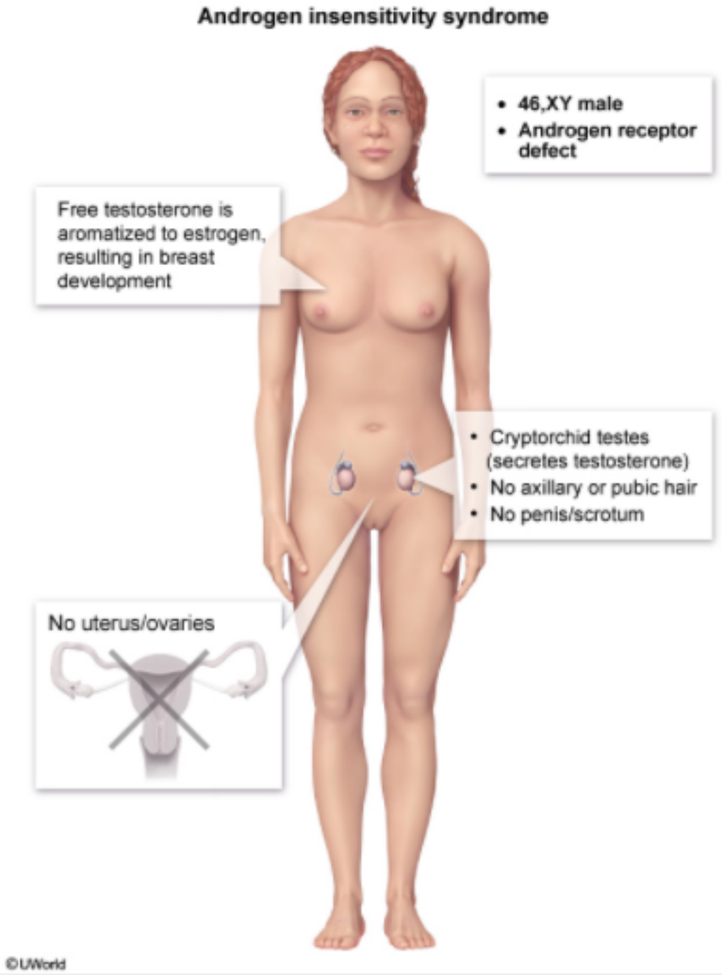

Zoom In | Zoom Out | Reset | Add To New Card | Existing Card

References

©UWorld

Exhibit Display

Pelvic endometriosis

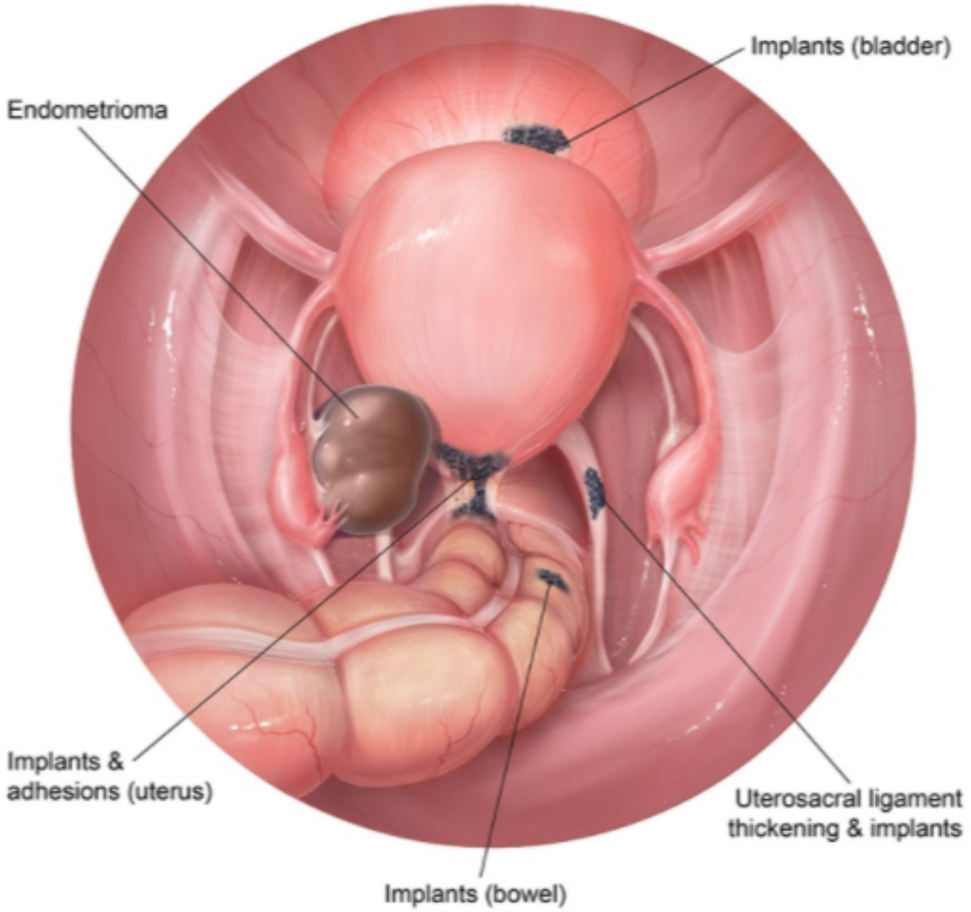

©UWorld

Zoom In | Zoom Out | Reset | Add To New Card | Existing Card

References

©UWorld

Exhibit Display

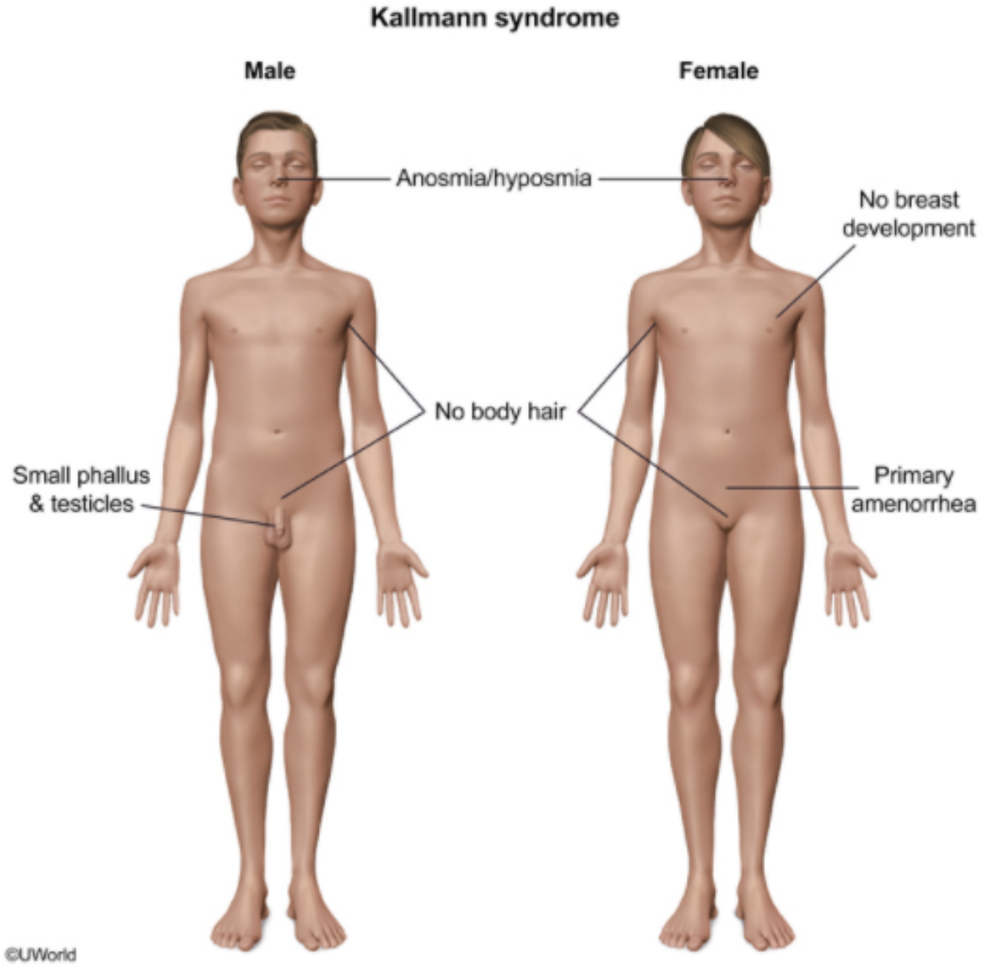

Zoom In | Zoom Out | Reset | Add To New Card | Existing Card

References

(Choice A) Patients with androgen insensitivity syndrome are genetically male but have a female phenotype due to resistance to testosterone. In adolescence, breast development results from peripheral conversion of testosterone to estrogen, but axillary and pubic hair is absent. Primary amenorrhea occurs due to a complete absence of Müllerian structures.

(Choice B) Asherman syndrome causes secondary amenorrhea through obstruction from scarring of the uterine cavity. This is typically a sequela of uterine infection (eg, postpartum endometritis) or procedures (eg, dilation and curettage).

(Choice C) Endometriosis is the presence of endometrial glands and stroma outside the uterus. It may cause severe dysmenorrhea (not amenorrhea) with lower abdominal cramps that begin 1-2 days before menses. A common site of endometrial implants is the pouch of Douglas, which presents as painful defecation, dyspareunia, and palpable nodularity on rectovaginal examination.

(Choice E) Kallmann syndrome occurs due to impaired synthesis of gonadotropin-releasing hormone by the hypothalamus. The condition presents with primary amenorrhea, absent secondary sexual characteristics, and an olfactory sensory defect.

(Choice F) Turner syndrome (45,XO) is the most common cause of primary amenorrhea. Affected individuals have short stature, webbed neck, shielded chest, and fibrotic ovaries, and do not develop secondary sexual characteristics.

Educational objective:
Imperforate hymen is caused by incomplete degeneration of the central portion of the fibrous tissue band connecting the walls of the vagina. Adolescent patients typically present with primary amenorrhea, normal secondary sexual characteristics, and cyclic abdominal or pelvic pain due to accumulation of menstrual blood in the vagina and uterus (eg, hematocolpos).

References

- Committee opinion: no. 562: Müllerian agenesis: diagnosis, management, and treatment.
- The presentation and management of complex female genital malformations.

Anatomy	Female Reproductive System & Breast	Amenorrhea
Subject	System	Topic

Copyright © UWorld. All rights reserved.

A 24-year-old woman at 38 weeks gestation delivers healthy twins vaginally after a prolonged labor. Shortly after the placenta is delivered, profuse vaginal bleeding and a boggy uterus are noted on examination. Uterine massage and uterotonic medications, including oxytocin, fail to stop the bleeding. The patient is taken to the operating room for a laparotomy. Bilateral ligation of which of the following arteries is most likely to control her bleeding and preserve her fertility?

A. Common iliac

B. External iliac

C. Internal iliac

D. Internal pudendal

E. Ovarian

Submit

A 24-year-old woman at 38 weeks gestation delivers healthy twins vaginally after a prolonged labor. Shortly after the placenta is delivered, profuse vaginal bleeding and a boggy uterus are noted on examination. Uterine massage and uterotonic medications, including oxytocin, fail to stop the bleeding. The patient is taken to the operating room for a laparotomy. Bilateral ligation of which of the following arteries is most likely to control her bleeding and preserve her fertility?

- A. Common iliac (1%)
- B. External iliac (3%)
- ✓ C. Internal iliac (58%)
- D. Internal pudendal (25%)
- E. Ovarian (10%)

Omitted
Correct answer
C

58%
Answered correctly

02 secs
Time Spent

04/23/2020
Last Updated

Explanation

Branches of the internal iliac artery in the female

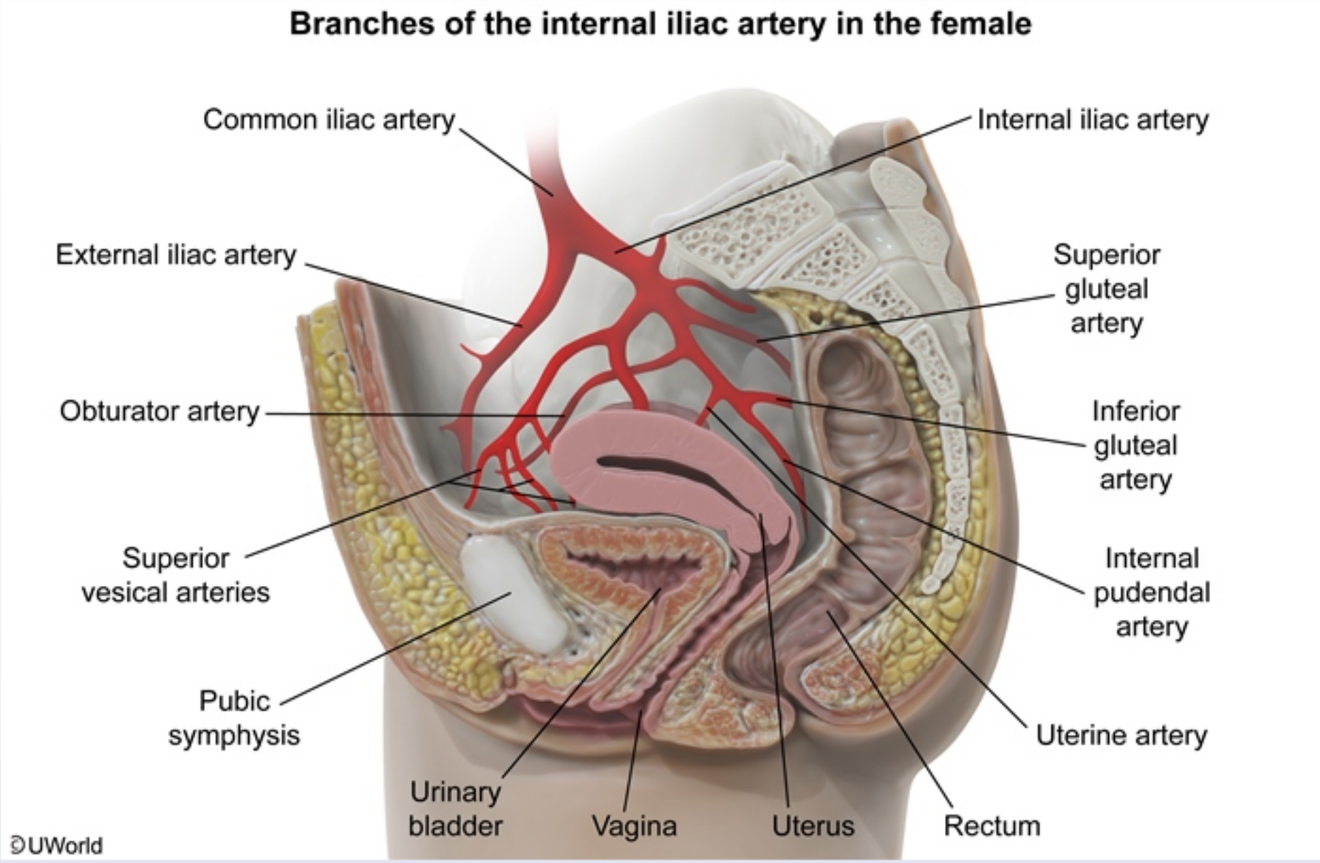

Postpartum hemorrhage is an obstetrical emergency and a leading cause of maternal mortality. Postpartum hemorrhage is frequently caused by failure of the uterus to contract and compress the placental site blood vessels. Risk factors include prolonged labor and twin gestation. These conditions lead to **uterine atony** (loss of uterine tone), characterized by a boggy uterus that cannot contract effectively after placental delivery. Surgery is indicated when medical management (uterine massage, uterotonic medications) of postpartum hemorrhage fails to control bleeding.

The pelvic organs are mainly supplied by the internal iliac arteries (also known as the hypogastric arteries). The uterine arteries, the major blood supply to the uterus, are branches of the **internal iliac arteries**. **Bilateral ligation** (eg, suturing) of the internal iliac arteries should **stop uterine**

Postpartum hemorrhage is an obstetrical emergency and a leading cause of maternal mortality. Postpartum hemorrhage is frequently caused by failure of the uterus to contract and compress the placental site blood vessels. Risk factors include prolonged labor and twin gestation. These conditions lead to **uterine atony** (loss of uterine tone), characterized by a boggy uterus that cannot contract effectively after placental delivery. Surgery is indicated when medical management (uterine massage, uterotonic medications) of postpartum hemorrhage fails to control bleeding.

The pelvic organs are mainly supplied by the internal iliac arteries (also known as the hypogastric arteries). The uterine arteries, the major blood supply to the uterus, are branches of the **internal iliac arteries**. **Bilateral ligation** (eg, suturing) of the internal iliac arteries should **stop uterine blood flow** and hemorrhage, thereby preventing the need for hysterectomy. The uterus has collateral blood flow from the ovarian arteries, which is sufficient to maintain uterine function after internal iliac ligation. Structures that are supplied by other branches of the internal iliac arteries have collateral circulation as well.

(Choices A and B) The aorta splits into the right and left common iliac arteries, which split into the internal and external iliac arteries. The external iliac artery becomes the femoral artery after it exits the pelvis and supplies the leg. Ligation of the common iliac artery would truncate blood supply to the pelvis and lower extremity. Ligation of the external iliac artery would cut off blood flow to the lower extremity but not affect uterine blood flow.

(Choice D) The internal pudendal artery branches off the anterior trunk of the internal iliac artery and runs through the sciatic foramina to supply blood to the perineum. Ligation of the internal pudendal artery would not affect uterine blood flow. Injury to the pudendal artery during vaginal delivery can cause a vulvar hematoma.

(Choice E) The uterus receives collateral blood supply from the ovarian artery, which runs from the abdominal aorta through the infundibulopelvic ligament (suspensory ligament) to supply the ovary. Ligation of the ovarian artery would risk necrosis of the ovaries and infertility. Blood flow through the ovarian artery is compromised during ovarian torsion.

Educational objective:
Postpartum hemorrhage is an obstetrical emergency. Bilateral ligation of the internal iliac artery can decrease uterine blood flow and control postpartum hemorrhage that is unresponsive to medical management (eg, uterine massage, uterotonic medications).

References

- Pelvic arterial ligations for severe post-partum hemorrhage. Indications and techniques.

A 63-year-old woman has a right-sided ovarian mass found incidentally on transvaginal ultrasound. The ultrasound revealed a normal uterus, a unilateral 3.5-cm complex ovarian mass with cystic and solid components, and no free fluid in the pelvis. The patient has no abdominal pain, changes in bowel or bladder habits, increased abdominal girth or bloating, or early satiety. Family history for ovarian cancer is negative. Physical examination shows a soft, nontender abdomen, small uterus, nonpalpable left adnexa, and enlarged, mobile right adnexa. Surgery is planned to remove the right ovary, including the mass. To avoid excessive bleeding during the oophorectomy, the surgeon should ligate which of the following structures?

- A. Mesosalpinx
- B. Ovarian ligament
- C. Round ligament of the uterus
- D. Suspensory ligament of the ovary
- E. Transverse cervical ligament

Submit

A 63-year-old woman has a right-sided ovarian mass found incidentally on transvaginal ultrasound. The ultrasound revealed a normal uterus, a unilateral 3.5-cm complex ovarian mass with cystic and solid components, and no free fluid in the pelvis. The patient has no abdominal pain, changes in bowel or bladder habits, increased abdominal girth or bloating, or early satiety. Family history for ovarian cancer is negative. Physical examination shows a soft, nontender abdomen, small uterus, nonpalpable left adnexa, and enlarged, mobile right adnexa. Surgery is planned to remove the right ovary, including the mass. To avoid excessive bleeding during the oophorectomy, the surgeon should ligate which of the following structures?

- A. Mesosalpinx (4%)
- B. Ovarian ligament (18%)
- C. Round ligament of the uterus (13%)
- ✓ D. Suspensory ligament of the ovary (62%)
- E. Transverse cervical ligament (1%)

Omitted
Correct answer
D

62%
Answered correctly

01 sec
Time Spent

03/29/2020
Last Updated

Explanation

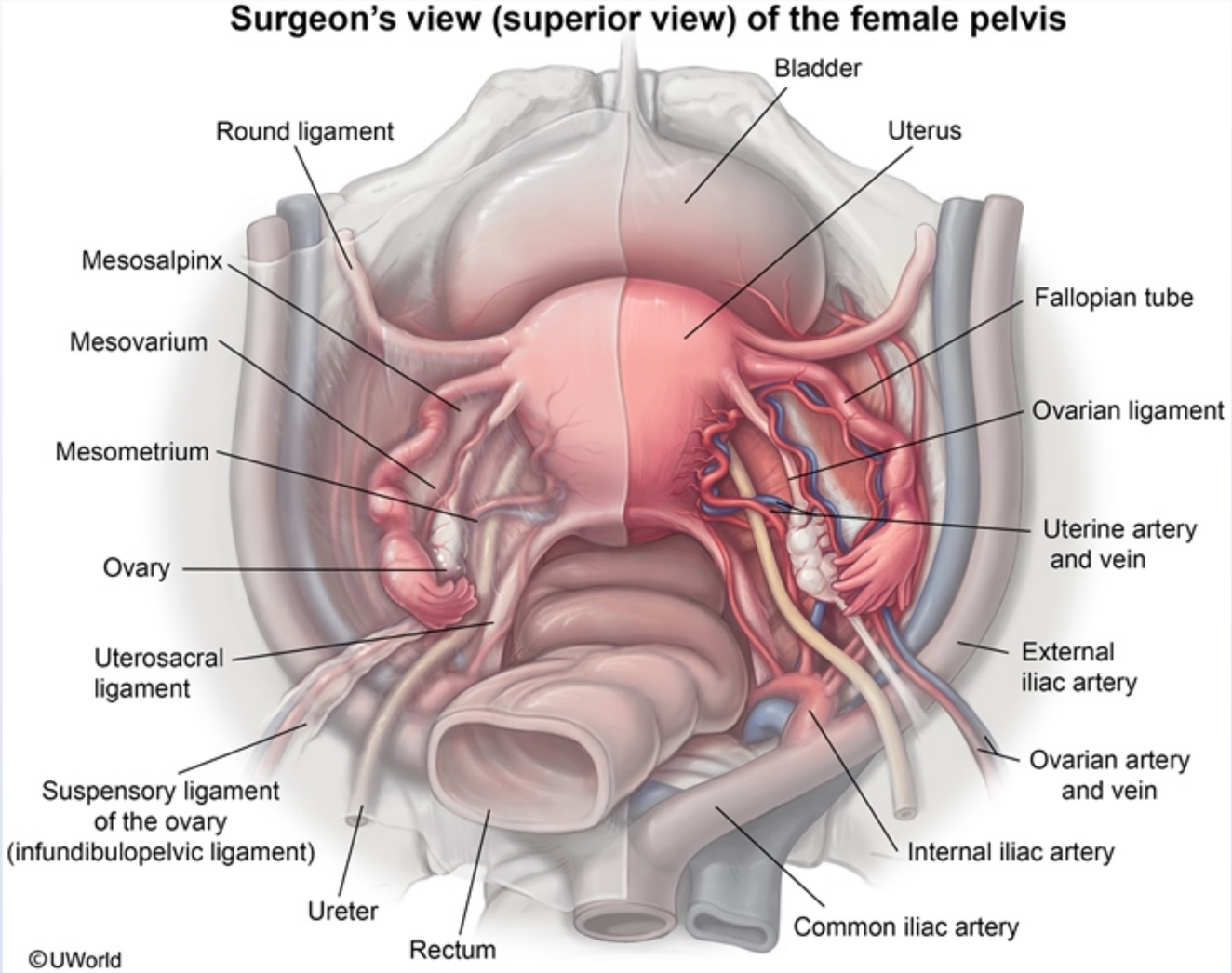

The broad ligament is a sheet of peritoneum that extends from the lateral uterine body and upper cervix to the pelvic sidewall. It is subdivided according to the following associated reproductive structures:

©UWorld

Rectum

The broad ligament is a sheet of peritoneum that extends from the lateral uterine body and upper cervix to the pelvic sidewall. It is subdivided according to the following associated reproductive structures:

- The mesosalpinx (descends from the fallopian tube)
- The mesoovarium (inferior to the mesosalpinx, covers the ovarian hilum)
- The mesometrium (inferior to the mesoovarium, extends from the lateral uterine body to the external iliac vessels and the proximal part of the round ligament)

The ovaries, located posterolaterally to the uterus, are suspended by the mesoovarium superiorly, the ovarian ligament medially, and the **suspensory ligament of the ovary** (also known as the **infundibulopelvic ligament**) laterally. The suspensory ligament of the ovary is a **fold of peritoneum** that attaches the ovary to the pelvic sidewall and **contains the ovarian artery** (major ovarian blood supply arising from the abdominal aorta entering the ovary at the hilum), **vein, lymphatics, and nerves**. The suspensory ligament of the ovary must be ligated to prevent heavy ovarian bleeding in an oophorectomy.

The ureter is in close proximity to the suspensory ligament of the ovary (medial at the level of the bifurcation of the common iliac artery). The ureter must be identified prior to ligation to avoid inadvertent ureteral transection.

(Choice A) The mesosalpinx is in the region of the broad ligament below the fallopian tubes, and it does not contain the major vascular supply to the ovary. An opening is made within a nonvascular portion of the mesosalpinx below the isthmic portion of the fallopian tube during a tubal ligation to ligate a segment of the tube.

(Choice B) The ovarian ligament is a band of connective tissue and smooth muscle that courses in the broad ligament and connects the ovary to the side of the uterus just below the fallopian tubes. It does not contain any named vessels or major blood supply to the ovary.

(Choice C) The round ligaments of the uterus originate at the uterine fundus, anteroinferior to the fallopian tubes, coursing through the inguinal canal out to the labia majora. They contain the artery of Sampson, which rarely is a source of major bleeding. The round ligaments are clamped and divided to enter the peritoneum of the broad ligament during a hysterectomy.

(Choice E) The transverse cervical ligament, also known as the cardinal ligament, extends from the cervix and lateral fornix of the vagina to the lateral pelvic walls. The uterine artery courses in its superior portion, necessitating division and ligation of this ligament during a hysterectomy. It is not relevant for adnexal surgery, which does not involve these lower structures.

The ureter is in close proximity to the suspensory ligament of the ovary (medial at the level of the bifurcation of the common iliac artery). The ureter must be identified prior to ligation to avoid inadvertent ureteral transection.

(Choice A) The mesosalpinx is in the region of the broad ligament below the fallopian tubes, and it does not contain the major vascular supply to the ovary. An opening is made within a nonvascular portion of the mesosalpinx below the isthmic portion of the fallopian tube during a tubal ligation to ligate a segment of the tube.

(Choice B) The ovarian ligament is a band of connective tissue and smooth muscle that courses in the broad ligament and connects the ovary to the side of the uterus just below the fallopian tubes. It does not contain any named vessels or major blood supply to the ovary.

(Choice C) The round ligaments of the uterus originate at the uterine fundus, anteroinferior to the fallopian tubes, coursing through the inguinal canal out to the labia majora. They contain the artery of Sampson, which rarely is a source of major bleeding. The round ligaments are clamped and divided to enter the peritoneum of the broad ligament during a hysterectomy.

(Choice E) The transverse cervical ligament, also known as the cardinal ligament, extends from the cervix and lateral fornix of the vagina to the lateral pelvic walls. The uterine artery courses in its superior portion, necessitating division and ligation of this ligament during a hysterectomy. It is not relevant for adnexal surgery, which does not involve these lower structures.

Educational objective:
The suspensory ligament of the ovary contains the ovarian artery, vein, lymphatics, and nerves. The ovarian artery is the major blood supply to the ovary and must be ligated during an oophorectomy to prevent heavy bleeding.

References

- ACOG Practice Bulletin: Management of adnexal masses.
- The incidental postmenopausal adnexal mass.

Anatomy	Female Reproductive System & Breast	Ovarian cancer
Subject	System	Topic

Copyright © UWorld. All rights reserved.

A 39-year-old nulliparous woman comes to the office due to pelvic pressure and constipation that have worsened over the past year. She finds it easier to defecate while pushing the vaginal canal with her fingers to get the stool out but still has an uncomfortable sensation of incomplete evacuation. Her menses occur every 28 days without heavy flow or severe pain. The patient has no pain with intercourse and uses condoms routinely for contraception. Her BMI is 24 kg/m^2. Examination shows an irregularly enlarged uterus and normal rectal tone. Which of the following is the most likely etiology of the patient's constipation?

A. Adenomyosis

B. Cervical carcinoma

C. Posterior subserosal uterine leiomyoma

D. Posterior vaginal wall prolapse (rectocele)

E. Rectovaginal endometriosis

Submit

A 39-year-old nulliparous woman comes to the office due to pelvic pressure and constipation that have worsened over the past year. She finds it easier to defecate while pushing the vaginal canal with her fingers to get the stool out but still has an uncomfortable sensation of incomplete evacuation. Her menses occur every 28 days without heavy flow or severe pain. The patient has no pain with intercourse and uses condoms routinely for contraception. Her BMI is 24 kg/m^2. Examination shows an irregularly enlarged uterus and normal rectal tone. Which of the following is the most likely etiology of the patient's constipation?

A. Adenomyosis (7%)

B. Cervical carcinoma (0%)

✓ C. Posterior subserosal uterine leiomyoma (59%)

D. Posterior vaginal wall prolapse (rectocele) (26%)

E. Rectovaginal endometriosis (5%)

Omitted
Correct answer
C

59%
Answered correctly

02 secs
Time Spent

02/18/2020
Last Updated

Explanation

The uterus is centrally located in the female pelvis, posterior to the bladder and anterior to the rectosigmoid colon. Uterine leiomyomas (fibroids) are monoclonal tumors; each fibroid is derived from a distinct progenitor cell. Fibroids can be located on the serosal surface of the uterus (subserosal), within the uterine wall (intramural), and below the endometrium (submucosal).

Subserosal fibroids often demonstrate exaggerated irregularity compared to intramural or submucosal fibroids, which are more constrained by

1
2
3
4
5
6
7
8
9
10
11
12
13
14
15
16
17
18
19
20
21
22

Explanation

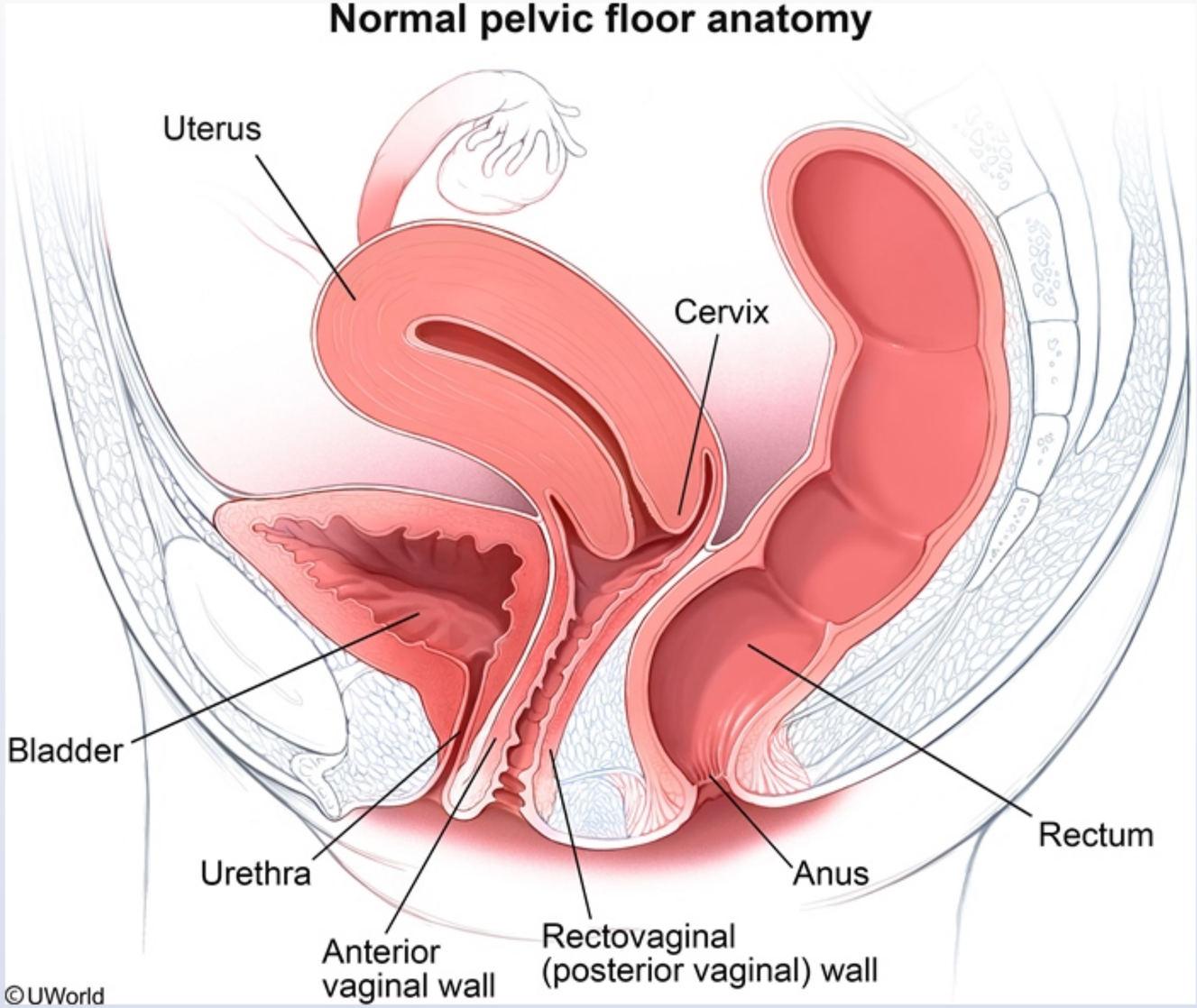

The uterus is centrally located in the female pelvis, posterior to the bladder and anterior to the rectosigmoid colon. Uterine leiomyomas (fibroids) are monoclonal tumors; each fibroid is derived from a distinct progenitor cell. Fibroids can be located on the serosal surface of the uterus (subserosal), within the uterine wall (intramural), and below the endometrium (submucosal).

Subserosal fibroids often demonstrate exaggerated irregularity compared to intramural or submucosal fibroids, which are more constrained by uterine tissue. **Irregular uterine enlargement** from fibroids can put pressure on adjacent organs, causing **bulk-related symptoms** (eg, pelvic pressure). Fibroids in the **posterior uterus** can put pressure on the **colon**, leading to **constipation**. Patients may be able to relieve this pressure by "splinting" to defecate, which involves manual deflection of the obstruction. Some posterior fibroids can displace the uterus upward and cause obstructive urinary symptoms, such as urgency or incomplete emptying.

Fibroids in other locations can cause reproductive difficulties if the uterine cavity is distorted (submucosal or intramural with an intracavitary component). Submucosal fibroids in particular can cause prolonged and/or heavy menstrual bleeding.

(Choice A) Adenomyosis typically presents with dysmenorrhea, abnormal uterine bleeding, and/or chronic pelvic pain in parous women. This patient's bulk-related symptoms are atypical for adenomyosis, and her irregularly enlarged uterus is inconsistent with the uniform, globular uterine enlargement that may accompany adenomyosis.

(Choice B) Advanced stage cervical cancer may cause bulk-related symptoms such as constipation and pelvic pressure. Abnormal vaginal bleeding, a visible cervical lesion, and/or human papillomavirus infection would make this diagnosis more likely.

(Choice D) Pelvic organ prolapse symptoms include pelvic pressure ("feeling a bulge or that something is falling out of the vagina"). Posterior vaginal wall prolapse (rectocele) can cause constipation; splinting is common but not uterine enlargement. In addition, premenopausal, nonobese nulliparous women are at lowest risk for pelvic organ prolapse.

(Choice E) Rectovaginal endometriosis may cause pelvic pain and constipation, especially around the time of menses. However, dyspareunia, dyschezia, and a palpable, tender nodularity would be more specific for endometriosis involving the rectovaginal septum. Endometriosis does not cause irregular uterine enlargement.

Educational objective:
Subserosal leiomyomas (fibroids) often cause irregular uterine enlargement, resulting in pelvic pressure. Fibroids arising from the posterior subserosal surface of the uterus can cause constipation due to pressure on the colon.

obstructive urinary symptoms, such as urgency or incomplete emptying.

Fibroids in other locations can cause reproductive difficulties if the uterine cavity is distorted (submucosal or intramural with an intracavitary component). Submucosal fibroids in particular can cause prolonged and/or heavy menstrual bleeding.

(Choice A) Adenomyosis typically presents with dysmenorrhea, abnormal uterine bleeding, and/or chronic pelvic pain in parous women. This patient's bulk-related symptoms are atypical for adenomyosis, and her irregularly enlarged uterus is inconsistent with the uniform, globular uterine enlargement that may accompany adenomyosis.

(Choice B) Advanced stage cervical cancer may cause bulk-related symptoms such as constipation and pelvic pressure. Abnormal vaginal bleeding, a visible cervical lesion, and/or human papillomavirus infection would make this diagnosis more likely.

(Choice D) Pelvic organ prolapse symptoms include pelvic pressure ("feeling a bulge or that something is falling out of the vagina"). Posterior vaginal wall prolapse (rectocele) can cause constipation; splinting is common but not uterine enlargement. In addition, premenopausal, nonobese nulliparous women are at lowest risk for pelvic organ prolapse.

(Choice E) Rectovaginal endometriosis may cause pelvic pain and constipation, especially around the time of menses. However, dyspareunia, dyschezia, and a palpable, tender nodularity would be more specific for endometriosis involving the rectovaginal septum. Endometriosis does not cause irregular uterine enlargement.

Educational objective:
Subserosal leiomyomas (fibroids) often cause irregular uterine enlargement, resulting in pelvic pressure. Fibroids arising from the posterior subserosal surface of the uterus can cause constipation due to pressure on the colon.

References

- An unusual cause of obstructed defecation

Anatomy	Female Reproductive System & Breast	Uterine fibroids
Subject	System	Topic

Copyright © UWorld. All rights reserved.

obstructive urinary symptoms, such as urgency or incomplete emptying

Exhibit Display

Rectocele, prolapse of posterior vaginal wall

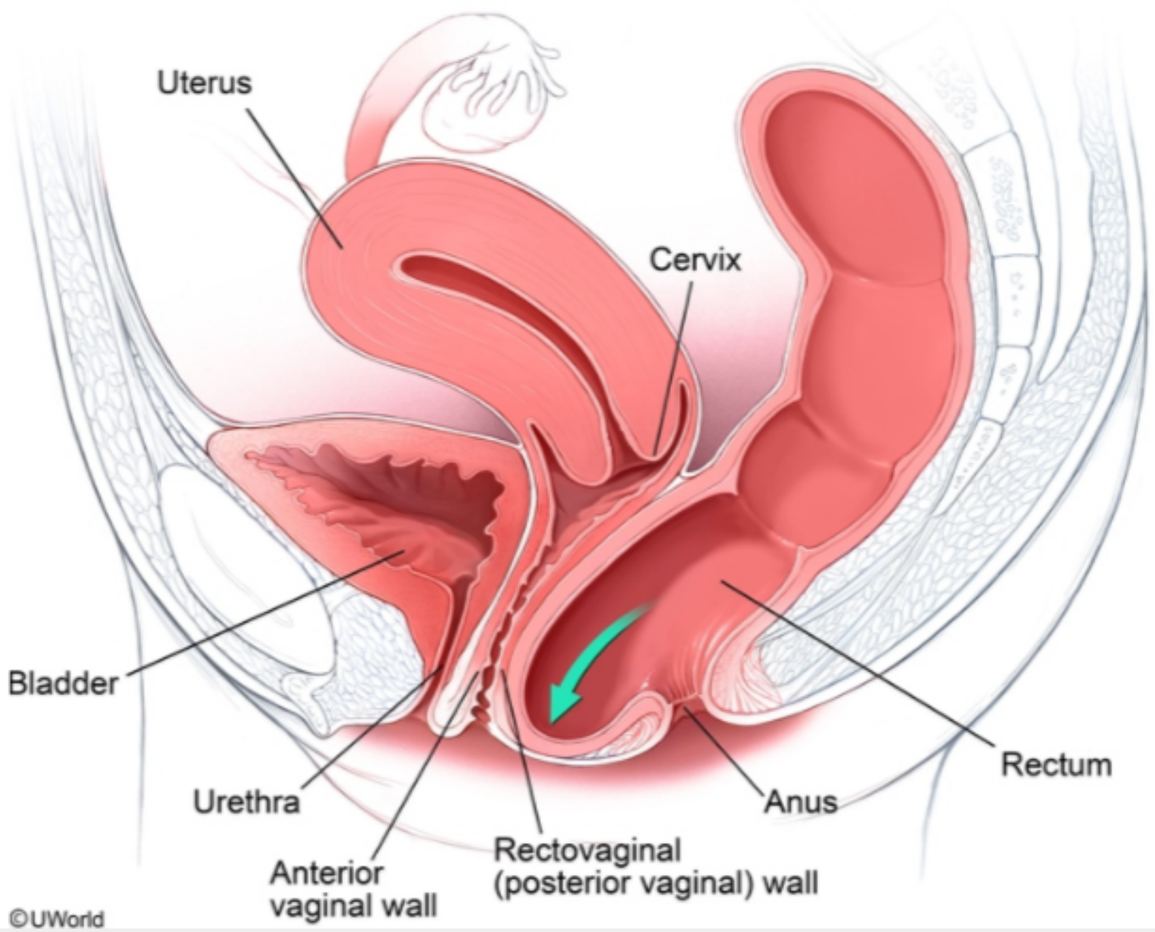

Zoom In | Zoom Out | Reset | Add To New Card | Existing Card

1
2
3
4
5
6
7
8
9
10
11
12
13
14
15
16
17
18
19
20
21
22

obstructive urinary symptoms, such as urgency or incomplete emptying

Exhibit Display

Pelvic endometriosis

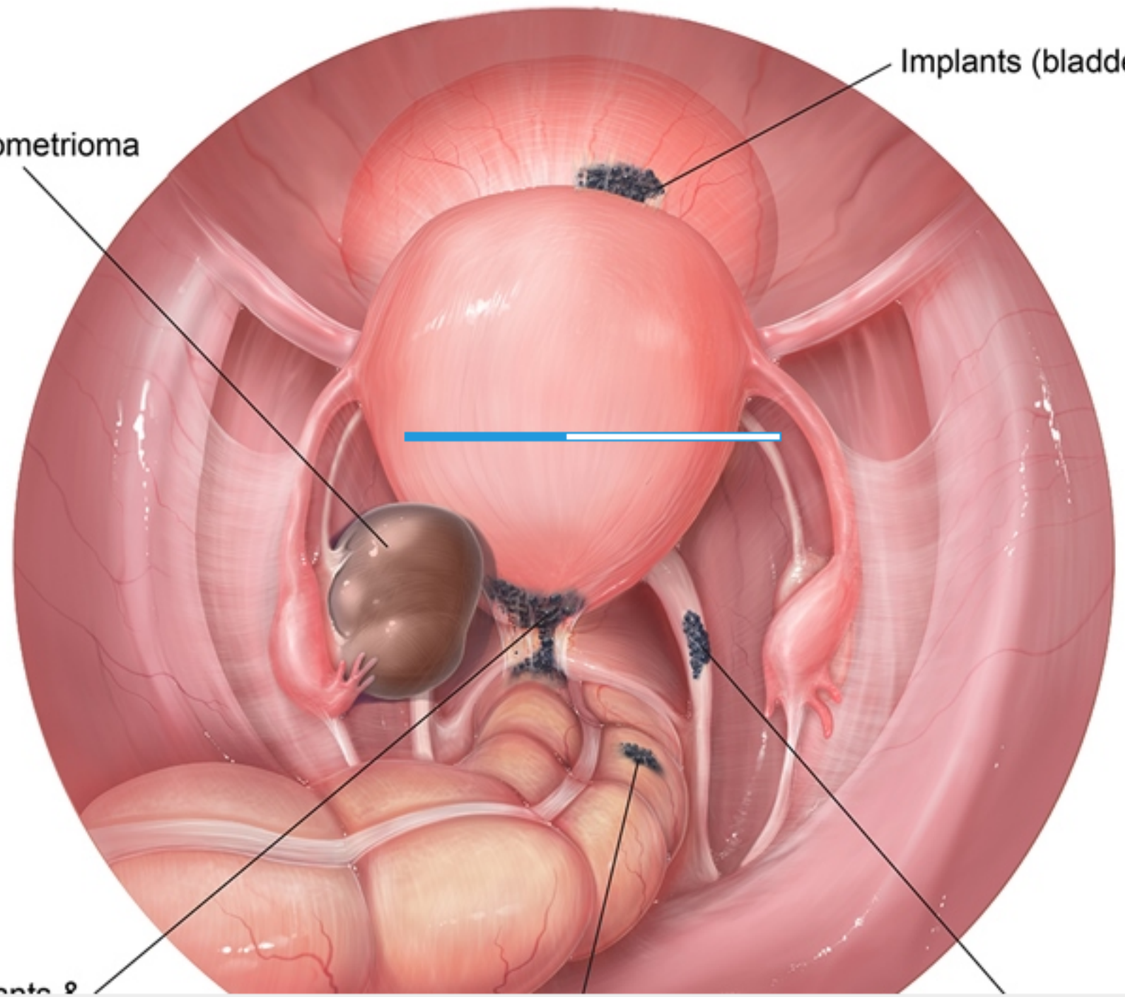

A 29-year-old woman, gravida 2, para 2, comes to the emergency department with fever, crampy abdominal pain, and right flank pain 8 days after an uncomplicated vaginal delivery. Her temperature is 38.3 C (101 F) and blood pressure is 110/60 mm Hg. A physical examination shows tenderness in the right lower quadrant and flank. She is hospitalized and given intravenous antibiotics for a presumed uterine infection, but her fever persists. Urine and blood cultures show no bacterial growth. A CT scan of her abdomen and pelvis reveals right ovarian vein thrombosis. If this patient remains untreated, she is at risk for extension of the thrombus into which of the following veins?

- A. Inferior vena cava
- B. Right common iliac vein
- C. Right internal iliac vein
- D. Right renal vein
- E. Right uterine vein

Submit

A 29-year-old woman, gravida 2, para 2, comes to the emergency department with fever, crampy abdominal pain, and right flank pain 8 days after an uncomplicated vaginal delivery. Her temperature is 38.3 C (101 F) and blood pressure is 110/60 mm Hg. A physical examination shows tenderness in the right lower quadrant and flank. She is hospitalized and given intravenous antibiotics for a presumed uterine infection, but her fever persists. Urine and blood cultures show no bacterial growth. A CT scan of her abdomen and pelvis reveals right ovarian vein thrombosis. If this patient remains untreated, she is at risk for extension of the thrombus into which of the following veins?

- ✓ A. Inferior vena cava (70%)
- B. Right common iliac vein (3%)
- C. Right internal iliac vein (16%)
- D. Right renal vein (8%)
- E. Right uterine vein (2%)

Omitted
Correct answer
A

70%
Answered correctly

02 secs
Time Spent

03/05/2020
Last Updated

Explanation

Postpartum ovarian vein thrombosis	
Risk	• Venous stasis (ovarian venous dilation) • Hypercoagulability (hormonally-mediated

Explanation

Postpartum ovarian vein thrombosis	
Risk factors	• Venous stasis (ovarian venous dilation) • Hypercoagulability (hormonally-mediated increase in clotting factors) • Endothelial damage (intrapartum vascular injury)
Clinical features	• Persistent fever after delivery • Localized abdominal/flank pain • No response to antibiotics

©UWorld

Thrombosis risk is markedly increased during pregnancy and puerperium due to **Virchow's triad**:

- Stasis from pregnancy-related venous dilation and compression of the inferior vena cava (IVC) and iliac veins by the gravid uterus
- Physiologic increases in factors VII, VIII, and X, as well as von Willebrand factor and fibrinogen (to protect from hemorrhage during miscarriage or childbirth)
- Endothelial damage due to uterine infection or intrapartum vascular trauma

Ovarian vein thrombosis is an example of septic pelvic thrombophlebitis, a complication that can occur via vaginal or cesarean delivery. Patients with ovarian vein thrombosis typically present with **fever** and **localized abdominal pain** one week after delivery and are usually hospitalized for a presumed uterine infection. When fever persists despite antibiotics, a CT or MRI scan can confirm the presence of a thrombus in the ovarian vein.

Ovarian venous drainage is asymmetric; the **left ovarian vein** drains into the **left renal vein (Choice D)** while the **right ovarian vein** drains directly into the **IVC**, and a clot can potentially extend into the IVC. Ovarian vein thrombosis is more commonly right-sided, but pulmonary emboli are uncommon and morbidity/mortality is low.

- Endothelial damage due to uterine infection or intrapartum vascular trauma

Ovarian vein thrombosis is an example of septic pelvic thrombophlebitis, a complication that can occur via vaginal or cesarean delivery. Patients with ovarian vein thrombosis typically present with **fever** and **localized abdominal pain** one week after delivery and are usually hospitalized for a presumed uterine infection. When fever persists despite antibiotics, a CT or MRI scan can confirm the presence of a thrombus in the ovarian vein.

Ovarian venous drainage is asymmetric; the **left ovarian vein** drains into the **left renal vein (Choice D)** while the **right ovarian vein** drains directly into the **IVC**, and a clot can potentially extend into the IVC. Ovarian vein thrombosis is more commonly right-sided, but pulmonary emboli are uncommon and morbidity/mortality is low.

(Choices B and C) In pregnancy, venous stasis and hypercoagulability predispose patients to proximal vein thrombosis (involving the iliac, femoral, or deep popliteal veins), which carries a risk of embolization into the pulmonary circulation. As the ovarian vasculature does not drain into the iliac vessels, there is no risk for clot extension to the common or internal iliac veins.

(Choice E) The uterine vein drains into the internal iliac vein. Extension of the clot to the uterine veins would require that the clot extend through the uterine venous plexus, which is less likely than direct extension through the ovarian vein toward the IVC.

Educational objective:
Venous stasis and hypercoagulability from pregnancy in addition to endothelial damage from delivery can cause ovarian vein thrombosis in the puerperium. Symptoms include fever and localized abdominal or flank pain. Most thrombosis is right-sided and can extend to the inferior vena cava; however, left ovarian vein thrombosis can extend to the left renal vein.

References

- Ovarian vein thrombosis.
- Venous thromboembolism in pregnancy.

Anatomy	Female Reproductive System & Breast	Ovarian vein thrombosis
Subject	System	Topic

Copyright © UWorld. All rights reserved.

- Endothelial damage due to uterine infection or intrapartum vascular trauma

Exhibit Display

Venous drainage of the female pelvis

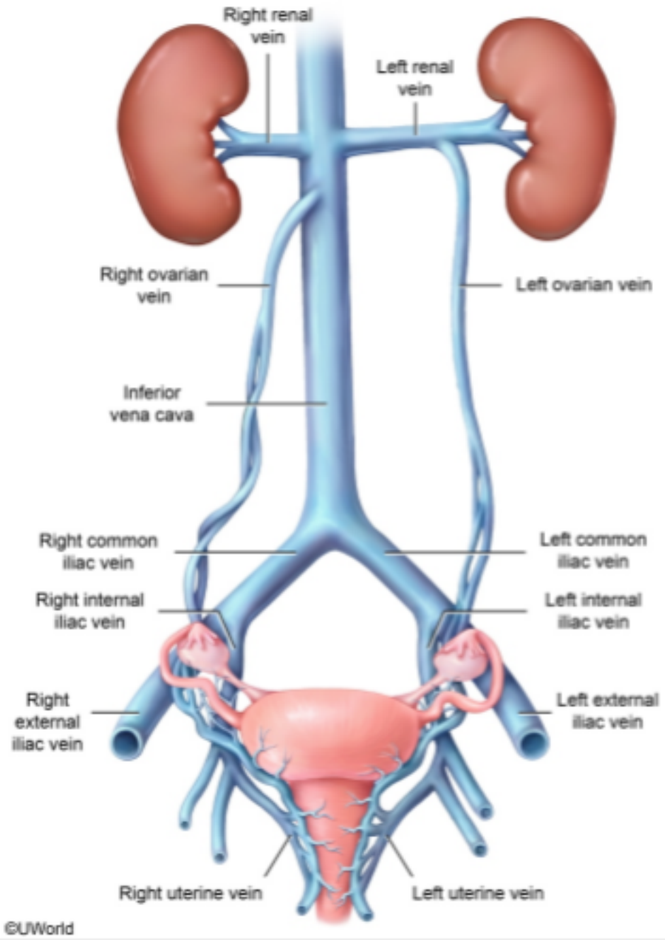

Zoom In | Zoom Out | Reset | Add To New Card | Existing Card

A 23-year-old man comes to the physician complaining of right-sided testicular swelling. He first noticed the swelling 1 week ago while getting ready for work. He denies any testicular pain or history of trauma. However, he has noticed a heavy, pressing sensation involving his scrotum and lower abdomen. Physical examination reveals asymmetric swelling of the right testis, and subsequent ultrasonography shows a solid testicular mass. If malignant, this patient's tumor is most likely to spread to which of the following lymph node groups?

- A. Superficial inguinal
- B. Deep inguinal
- C. External iliac
- D. Common iliac
- E. Inferior mesenteric
- F. Para-aortic

Submit

A 23-year-old man comes to the physician complaining of right-sided testicular swelling. He first noticed the swelling 1 week ago while getting ready for work. He denies any testicular pain or history of trauma. However, he has noticed a heavy, pressing sensation involving his scrotum and lower abdomen. Physical examination reveals asymmetric swelling of the right testis, and subsequent ultrasonography shows a solid testicular mass. If malignant, this patient's tumor is most likely to spread to which of the following lymph node groups?

- A. Superficial inguinal (7%)
- B. Deep inguinal (7%)
- C. External iliac (1%)
- D. Common iliac (1%)
- E. Inferior mesenteric (1%)
- ✓ F. Para-aortic (80%)

Omitted
Correct answer
F

80%
Answered correctly

02 secs
Time Spent

02/05/2020
Last Updated

Explanation

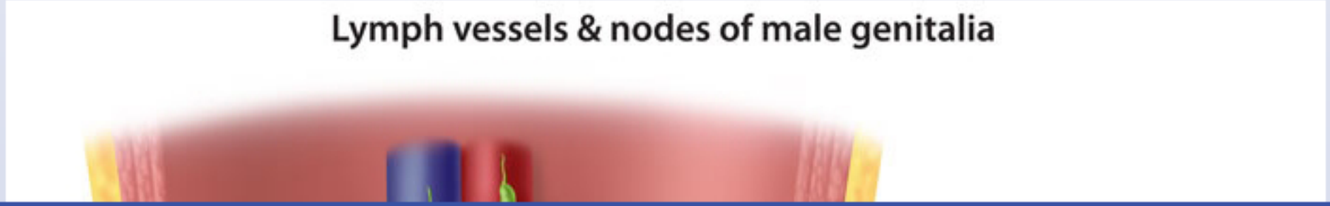

Lymph vessels & nodes of male genitalia

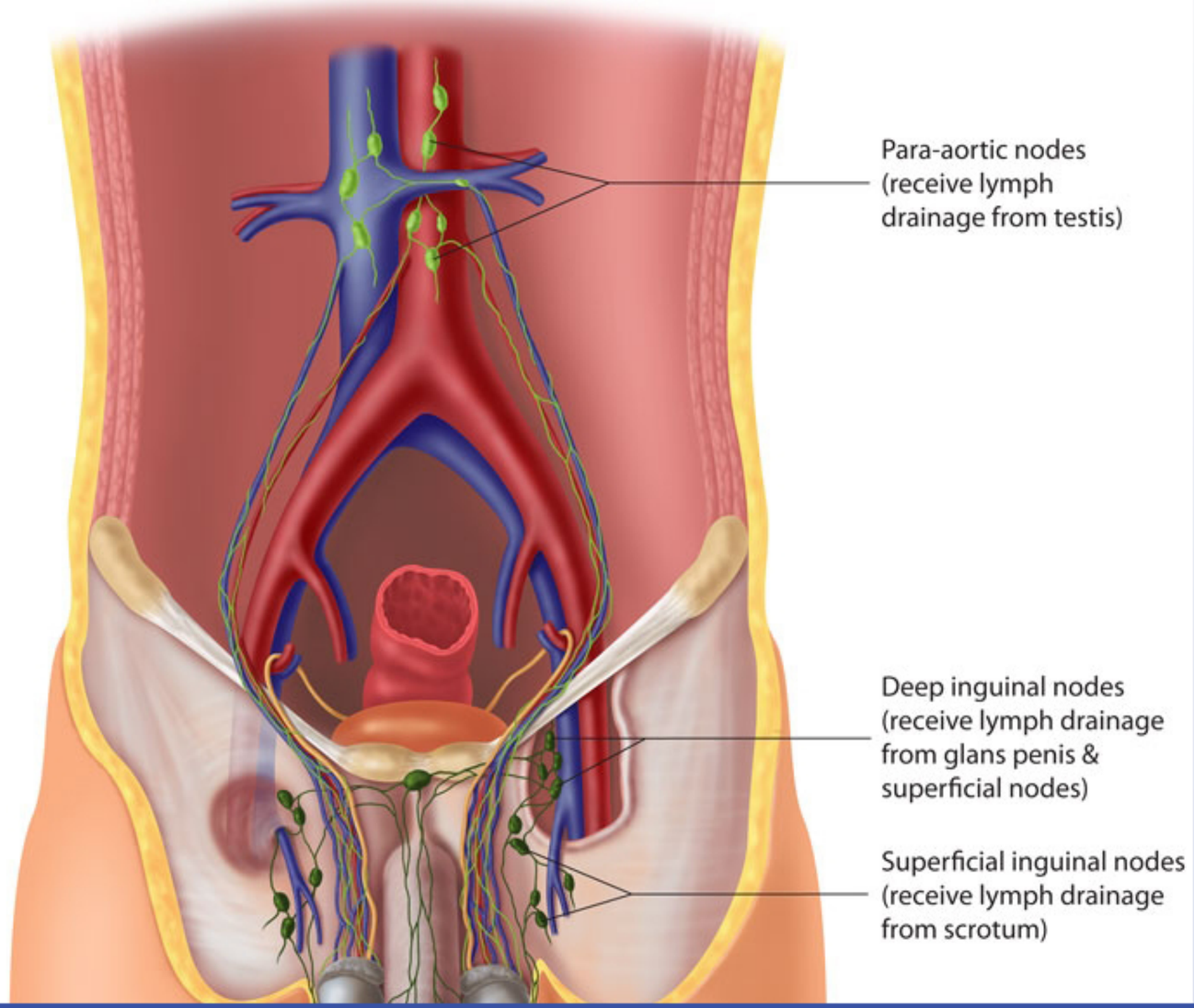

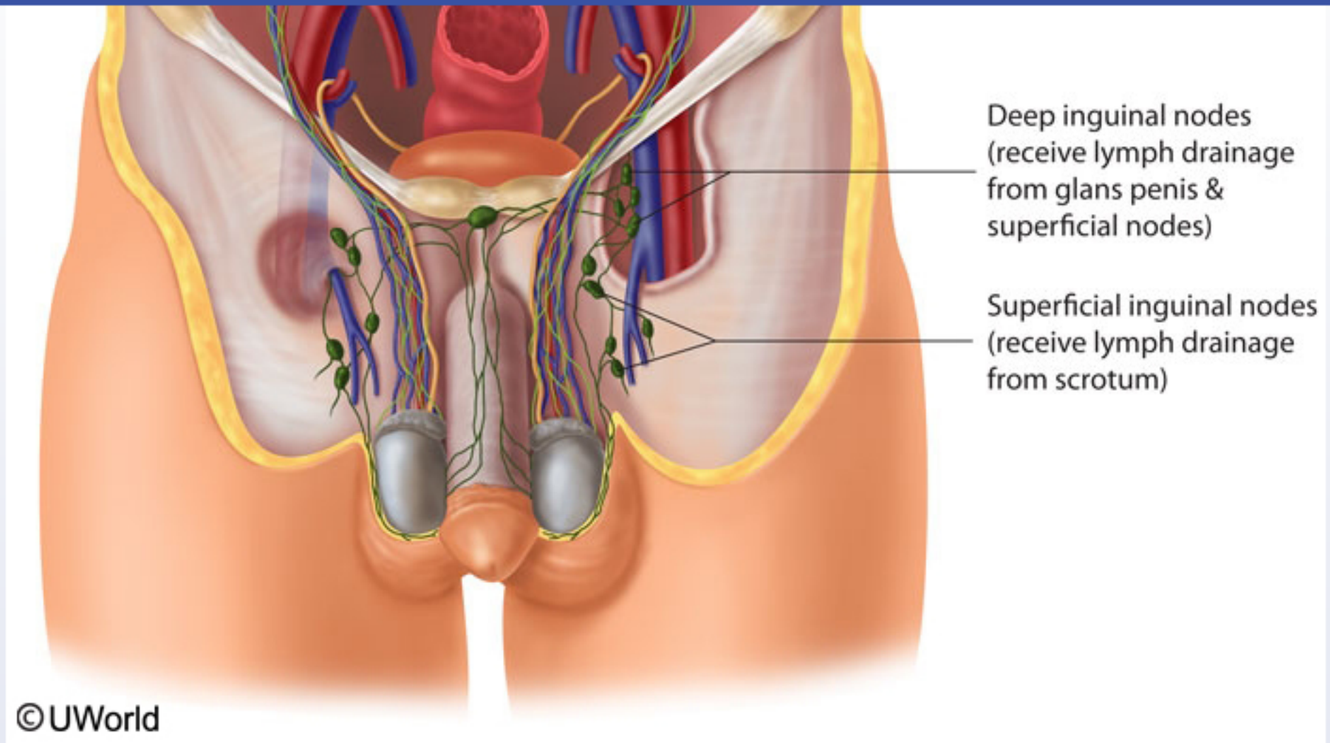

In general, the lymph drainage from a particular organ follows the path of the arterial supply to that site. During fetal development, the testes originate within the retroperitoneum and establish their arterial supply from the abdominal aorta. The testes subsequently descend through the inguinal canals into the scrotum, taking with them their arterial, venous, and lymphatic supplies. Thus, lymph from the testes drains through lymph channels directly back to the para-aortic (retroperitoneal) lymph nodes.

(Choice A) The superficial inguinal lymph nodes are located on the anterior thigh inferior to the inguinal ligament. These nodes drain nearly all cutaneous structures inferior to the umbilicus, including the external genitalia and the anus up to the pectinate line.

(Choice B) The deep inguinal nodes reside under the fascia lata on the medial side of the femoral vein. They receive afferents from the superficial inguinal nodes and deep lymphatic trunks along the femoral vessels. The lymphatics from the glans penis and clitoris also drain directly to these nodes.

©UWorld

In general, the lymph drainage from a particular organ follows the path of the arterial supply to that site. During fetal development, the testes originate within the retroperitoneum and establish their arterial supply from the abdominal aorta. The testes subsequently descend through the inguinal canals into the scrotum, taking with them their arterial, venous, and lymphatic supplies. Thus, lymph from the testes drains through lymph channels directly back to the para-aortic (retroperitoneal) lymph nodes.

(Choice A) The superficial inguinal lymph nodes are located on the anterior thigh inferior to the inguinal ligament. These nodes drain nearly all cutaneous structures inferior to the umbilicus, including the external genitalia and the anus up to the pectinate line.

(Choice B) The deep inguinal nodes reside under the fascia lata on the medial side of the femoral vein. They receive afferents from the superficial inguinal nodes and deep lymphatic trunks along the femoral vessels. The lymphatics from the glans penis and clitoris also drain directly to these nodes.

(Choice C) The external iliac nodes drain the superficial and deep inguinal nodes and the deep lymphatics of the abdominal wall below the umbilicus.

(Choice D) The common iliac nodes are located alongside the common iliac artery and drain the internal and external iliac nodes.

(Choice E) The inferior mesenteric nodes drain the structures supplied with arterial blood by branches of the inferior mesenteric artery (eg, the left colic, sigmoid, and superior rectal arteries). Thus, these nodes drain the descending and sigmoid colon as well as the upper part of the rectum. Their efferents drain to pre-aortic nodes.

Educational objective:
Lymph from the testes drains through lymph channels directly back to the para-aortic lymph nodes. In contrast, lymph from the scrotum drains to the superficial inguinal lymph nodes.

Anatomy	Male Reproductive System	Lymphatic drainage
Subject	System	Topic

Copyright © UWorld. All rights reserved.

A 45-year-old man is brought to the emergency department after a motor vehicle accident. He is unable to void and complains of a full bladder sensation. Foley catheter placement is attempted, but the procedure is aborted once resistance is encountered and the patient begins complaining of pain. A CT scan of his chest, abdomen, and pelvis shows a left hemothorax and pelvic fracture. This patient is most likely to have an injury involving which of the following portions of the urogenital tract?

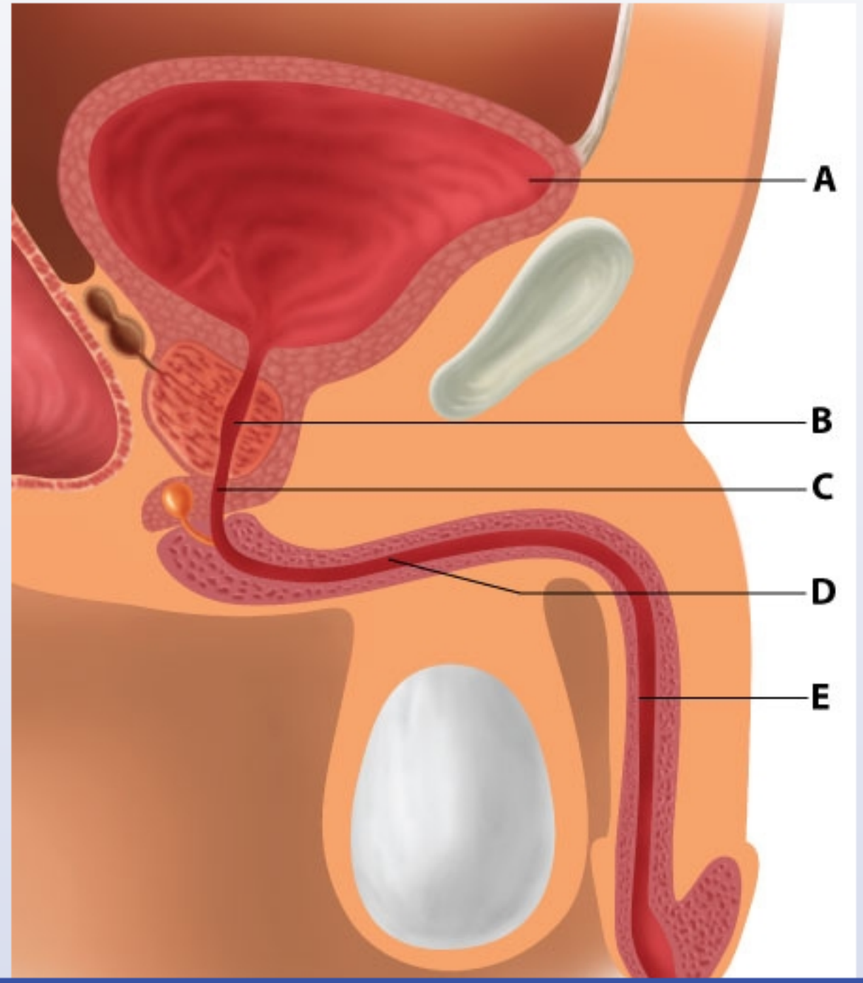

1
2
3
4
5
6
7
8
9
10
11
12
13
14
15
16
17
18
19
20
21
22

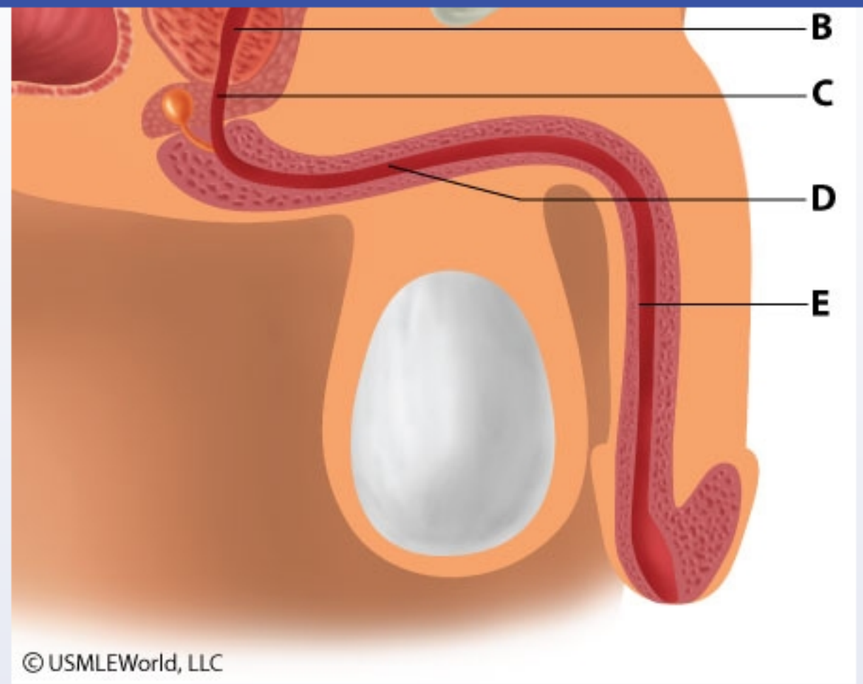

A. A

B. B

C. C

D. D

E. E

Submit

1
2
3
4
5
6
7
8
9
10
11
12
13
14
15
16
17
18
19
20
21
22

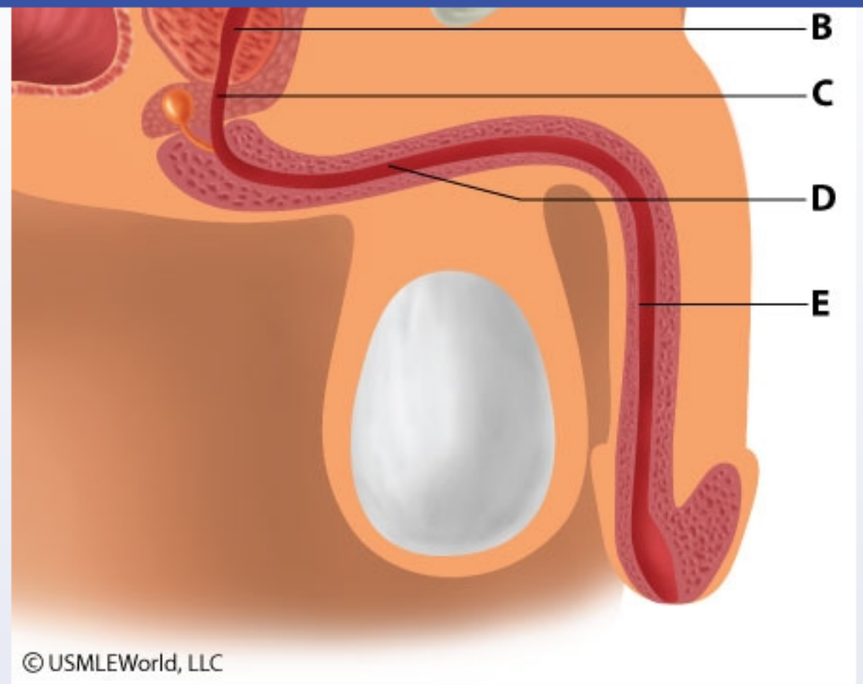

A. A (6%)
B. B (17%)
✓ C. C (54%)
D. D (20%)
E. E (1%)

Omitted
Correct answer

54%
Answered correctly

14 secs
Time Spent

06/04/2020
Last Updated

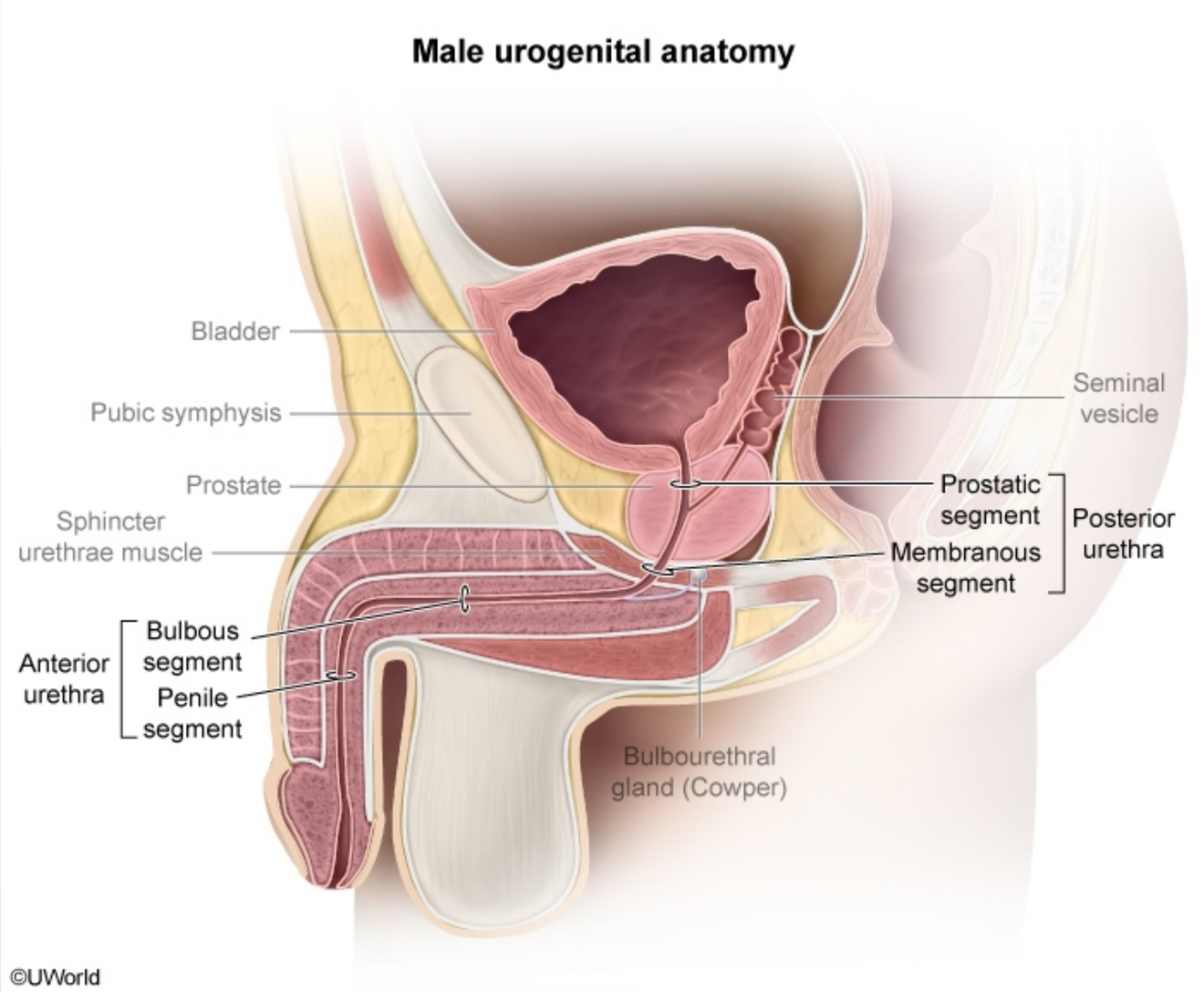

The presence of a pelvic fracture and inability to void despite the sensation of a full bladder is suggestive of urethral injury. Additional signs of

The presence of a pelvic fracture and inability to void despite the sensation of a full bladder is suggestive of urethral injury. Additional signs of urethral injury include the presence of blood at the urethral meatus and a high-riding, boggy prostate (caused by hematoma formation below the gland). If urethral injury is suspected, placement of a Foley catheter is contraindicated and should not be attempted as it can worsen the injury; a retrograde urethrogram should be performed first to assess urethral integrity.

Urethral injuries most commonly occur in men because of their longer urethral length and are divided into anterior and posterior urethral injuries. The posterior urethra is located above the bulb of the penis, and the anterior urethra lies within the bulb and the remainder of the corpus spongiosum. The posterior urethra is further divided into the prostatic and membranous segments; the anterior urethra is divided into bulbous and penile segments. In contrast to the prostatic and bulbous segments, the membranous segment is relatively unsupported by the adjacent tissues and is the weakest point of the posterior urethra. Trauma to the pelvis severe enough to cause fracture often results in disruption of the posterior urethra at the bulbomembranous junction.

(Choice A) Injury of the anterior bladder wall is common with pelvic fractures and is usually associated with extraperitoneal leakage of urine. Superior bladder wall ruptures often occur with abdominal trauma when the bladder is full and result in leakage of urine into the intraperitoneal cavity. This patient's full bladder sensation and inability to pass a Foley catheter makes a urethral injury more likely.

(Choice B) The prostatic urethral segment is strengthened by the surrounding prostate tissue and thus is less likely to be damaged from a pelvic fracture.

(Choice D) Although the bulbous urethral segment is reinforced by the surrounding corpus spongiosum, it is susceptible to crushing injuries when the perineum is struck forcefully (ie, straddle injury). Common mechanisms include falling on the crossbar of a bicycle or the top of a fence.

(Choice E) The penile urethral segment is most commonly injured due to penetrating trauma or instrumentation.

Educational objective:
Injury to the posterior urethra is associated with pelvic fractures, and the anterior urethra is most commonly damaged in straddle injuries. Inability to void with a full bladder sensation, a high-riding boggy prostate, and blood at the urethral meatus are suggestive of urethral injury, particularly in the presence of a pelvic fracture. If urethral injury is suspected, placement of a Foley catheter is contraindicated.

References

- Diagnosis and classification of urethral injuries.

spongiosum. The posterior urethra is further divided into the prostatic and membranous segments; the anterior urethra is divided into bulbous and penile segments. In contrast to the prostatic and bulbous segments, the membranous segment is relatively unsupported by the adjacent tissues and is the weakest point of the posterior urethra. Trauma to the pelvis severe enough to cause fracture often results in disruption of the posterior urethra at the bulbomembranous junction.

(Choice A) Injury of the anterior bladder wall is common with pelvic fractures and is usually associated with extraperitoneal leakage of urine. Superior bladder wall ruptures often occur with abdominal trauma when the bladder is full and result in leakage of urine into the intraperitoneal cavity. This patient's full bladder sensation and inability to pass a Foley catheter makes a urethral injury more likely.

(Choice B) The prostatic urethral segment is strengthened by the surrounding prostate tissue and thus is less likely to be damaged from a pelvic fracture.

(Choice D) Although the bulbous urethral segment is reinforced by the surrounding corpus spongiosum, it is susceptible to crushing injuries when the perineum is struck forcefully (ie, straddle injury). Common mechanisms include falling on the crossbar of a bicycle or the top of a fence.

(Choice E) The penile urethral segment is most commonly injured due to penetrating trauma or instrumentation.

Educational objective:
Injury to the posterior urethra is associated with pelvic fractures, and the anterior urethra is most commonly damaged in straddle injuries. Inability to void with a full bladder sensation, a high-riding boggy prostate, and blood at the urethral meatus are suggestive of urethral injury, particularly in the presence of a pelvic fracture. If urethral injury is suspected, placement of a Foley catheter is contraindicated.

References

- Diagnosis and classification of urethral injuries.
- Lower urinary tract injuries following blunt trauma: a review of contemporary management.

Anatomy	Male Reproductive System	Urethral injury
Subject	System	Topic

Copyright © UWorld. All rights reserved.

1
2
3
4
5
6
7
8
9
10
11
12
13
14
15
16
17
18
19
20
21
22

A 61-year-old woman comes to the office due to skin dimpling on the right breast. She first noticed the skin changes 3 months ago while on vacation and is concerned that they have not resolved. The patient does not use tobacco, alcohol, or illicit drugs. She exercises regularly and takes a daily multivitamin. Her last menstrual period was 8 years ago. Physical examination shows a prominent, nontender skin retraction without discoloration or swelling of the right breast. There is also a 6-cm irregular, immobile, firm mass in the right upper outer quadrant of the breast. The left breast appears normal. This patient's skin findings are likely due to malignant infiltration of which of the following structures?

A. Axillary lymph nodes

B. Lactiferous ducts

C. Mammary vein

D. Nipple

E. Suspensory ligaments

Submit

A 61-year-old woman comes to the office due to skin dimpling on the right breast. She first noticed the skin changes 3 months ago while on vacation and is concerned that they have not resolved. The patient does not use tobacco, alcohol, or illicit drugs. She exercises regularly and takes a daily multivitamin. Her last menstrual period was 8 years ago. Physical examination shows a prominent, nontender skin retraction without discoloration or swelling of the right breast. There is also a 6-cm irregular, immobile, firm mass in the right upper outer quadrant of the breast. The left breast appears normal. This patient's skin findings are likely due to malignant infiltration of which of the following structures?

- A. Axillary lymph nodes (12%)
- B. Lactiferous ducts (15%)
- C. Mammary vein (0%)
- D. Nipple (1%)
- ✓ E. Suspensory ligaments (69%)

Omitted
Correct answer
E

69%
Answered correctly

02 secs
Time Spent

01/29/2020
Last Updated

Explanation

Breast cancer spread to suspensory ligament

Suspensory

1
2
3
4
5
6
7
8
9
10
11
12
13
14
15
16
17
18
19
20
21
22

Breast cancer spread to suspensory ligament

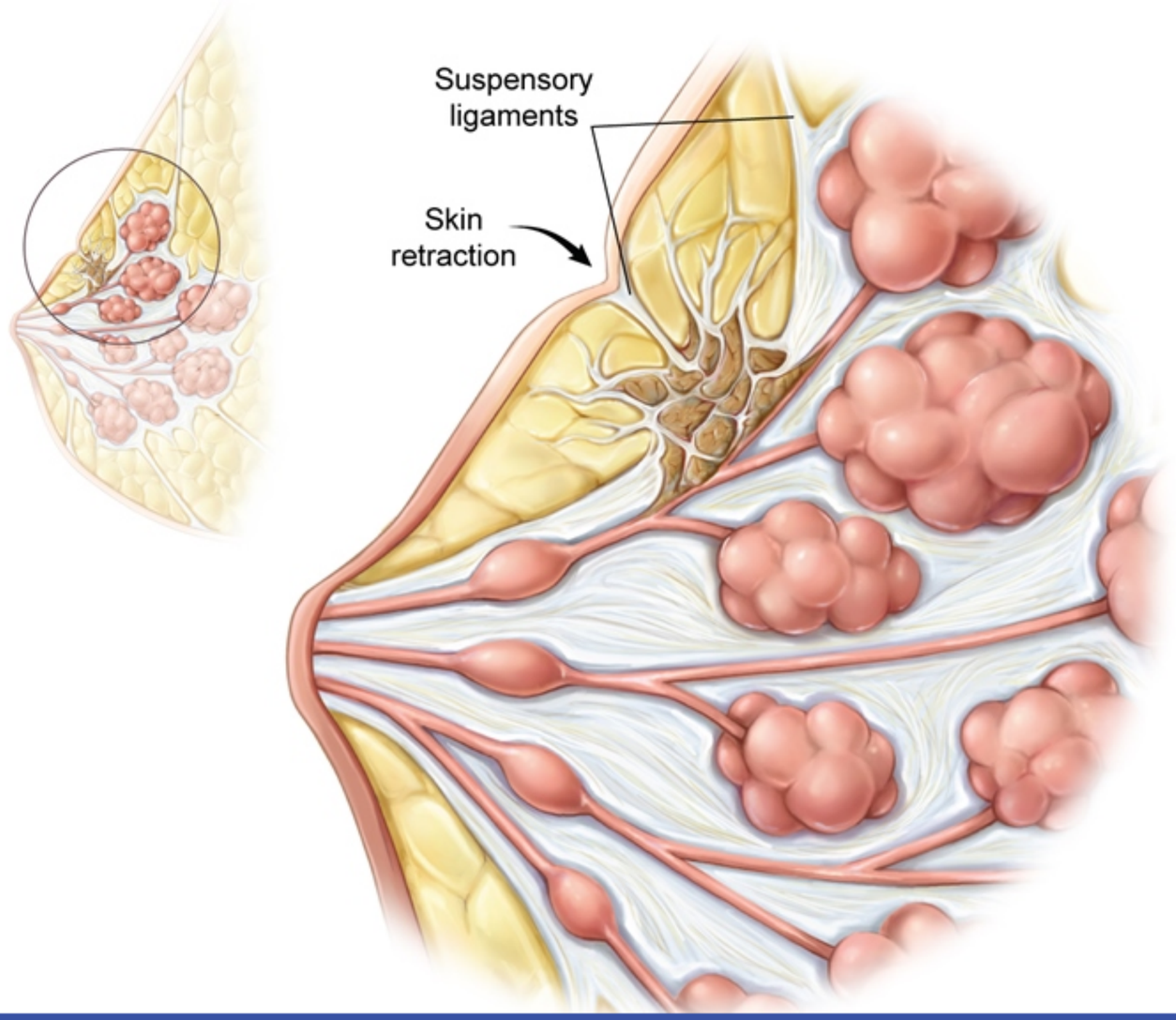

©UWorld

Breast cancer is the most commonly diagnosed malignancy in women in the United States and the second most common cause of cancer death in women. **Invasive breast carcinoma** typically presents as an irregularly shaped, adherent breast mass. The upper outer quadrants of the breast are the most common site of breast cancer. Overlying **skin retractions** (puckering) signal involvement of **suspensory ligaments** of the breast (ie, **Cooper ligaments**). Malignant infiltration of these ligaments causes fibrosis and shortening, leading to traction on the skin with distortion in breast contour.

(Choice A) Axillary lymph nodes are the most common site of metastasis for breast cancer. As malignant cells spread through the lymphatics, they can block cutaneous lymphatic flow, causing peau d'orange (thickened, dimpled skin like an orange peel). However, this finding is distinct from skin retractions and is associated with discoloration and swelling of the breast.

(Choices B and D) Lactiferous ducts connect the nipple to the mammary lobules to allow lactation. Malignant spread of ductal carcinoma through the ductal system may cause nipple discharge, whereas spread to the nipple surface causes Paget disease of the nipple (eg, eczematous exudate over the nipple and areola).

(Choice C) The internal mammary vein runs along the thoracic lymphatics, draining the medial portions of the breast, and may be a site of metastasis from lesions in that area. Spread to the vasculature often results in distant hematogenous metastasis.

Educational objective:
Invasive breast carcinoma typically presents as an irregularly shaped, adherent breast mass, most commonly in the upper outer quadrant. Malignant infiltration of suspensory ligaments of the breast can cause skin retractions.

References

- Breast anatomy for the interventionalist.

Anatomy	Female Reproductive System & Breast	Breast cancer
Subject	System	Topic

Copyright © UWorld. All rights reserved.

1
2
3
4
5
6
7
8
9
10
11
12
13
14
15
16
17
18
19
20
21
22

Exhibit Display

Zoom In | Zoom Out | Reset | Add To New Card | Existing Card

A 28-year-old woman comes to the office due to a 4-month history of amenorrhea. She has also had a whitish nipple discharge from both breasts. The patient has taken several pregnancy tests at home that have been negative. She has also had increased fatigue, depressed mood, and weight gain over this time. The patient has had no headaches or vision changes. She has no prior medical problems and takes no medications. On physical examination, there is thinning of the outer third of the eyebrows. The thyroid is enlarged and nontender to palpation. Abdominal and pelvic examinations are normal. The skin appears dry. Laboratory results are as follows:

Beta-hCG, serum	negative
Thyroxine (T4)	2.5 μg/dL
TSH	11.0 μU/mL
Prolactin	30 ng/mL (<20 ng/mL)
Antithyroid peroxidase antibodies	positive

Which of the following is the most likely mechanism causing this patient's elevated prolactin level?

- A. Activation of lactotrophs by antithyroid peroxidase antibodies
- B. Binding of dopamine receptors by antithyroid peroxidase antibodies
- C. Inhibition of dopamine release by TSH
- D. Stimulation of lactotrophs by thyrotropin-releasing hormone (TRH)
- E. TRH-induced overproduction of dopamine
- F. TSH-mediated activation of lactotrophs

Submit

A 28-year-old woman comes to the office due to a 4-month history of amenorrhea. She has also had a whitish nipple discharge from both breasts. The patient has taken several pregnancy tests at home that have been negative. She has also had increased fatigue, depressed mood, and weight gain over this time. The patient has had no headaches or vision changes. She has no prior medical problems and takes no medications. On physical examination, there is thinning of the outer third of the eyebrows. The thyroid is enlarged and nontender to palpation. Abdominal and pelvic examinations are normal. The skin appears dry. Laboratory results are as follows:

Beta-hCG, serum	negative
Thyroxine (T4)	2.5 μg/dL
TSH	11.0 μU/mL
Prolactin	30 ng/mL (<20 ng/mL)
Antithyroid peroxidase antibodies	positive

Which of the following is the most likely mechanism causing this patient's elevated prolactin level?

A. Activation of lactotrophs by antithyroid peroxidase antibodies (3%)
B. Binding of dopamine receptors by antithyroid peroxidase antibodies (5%)
C. Inhibition of dopamine release by TSH (24%)
✓ D. Stimulation of lactotrophs by thyrotropin-releasing hormone (TRH) (49%)
E. TRH-induced overproduction of dopamine (2%)
F. TSH-mediated activation of lactotrophs (14%)

Omitted 49% 02 secs 03/21/2020

1
2
3
4
5
6
7
8
9
10
11
12
13
14
15
16
17
18
19
20
21
22

Prolactin

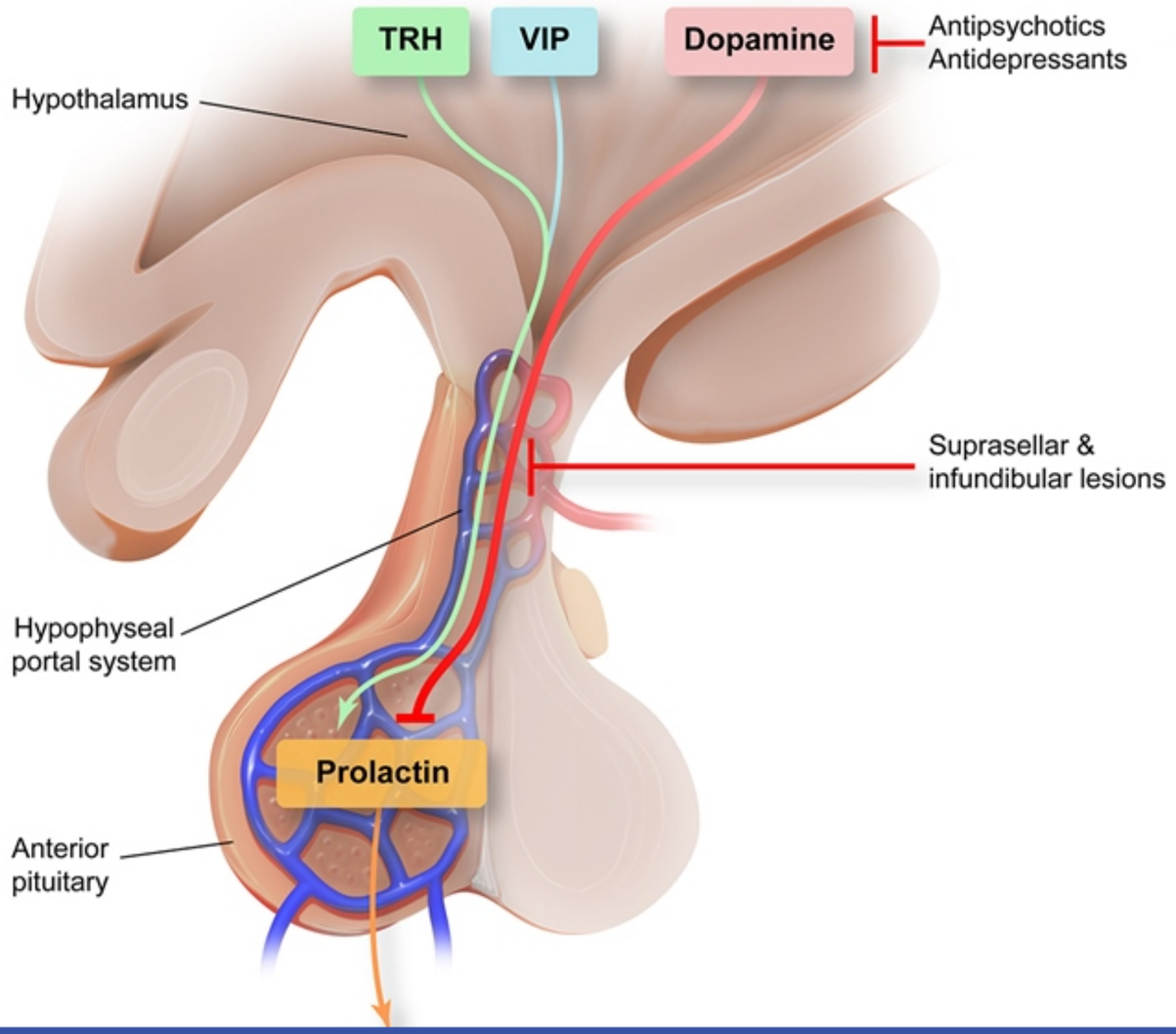

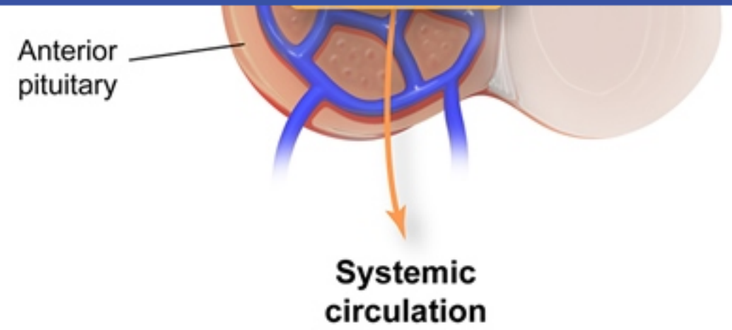

TRH = thyrotropin-releasing hormone; **VIP** = vasoactive intestinal peptide.

©UWorld

This patient has symptoms of hypothyroidism (eg, fatigue, weight gain, goiter, thinning of outer eyebrow edges). Her low thyroxine (T4), elevated TSH, and antithyroid peroxidase antibodies are further indicative of **primary hypothyroidism** from chronic autoimmune (Hashimoto) thyroiditis. In patients with primary hypothyroidism, there is a compensatory increase in hypothalamic thyrotropin-releasing hormone (TRH) production as thyroid hormone levels fall, stimulating increased secretion of TSH by the pituitary.

Prolactin is regulated primarily by the inhibitory effects of dopaminergic neurons from the hypothalamus. However, lactotroph cells express TRH receptors, and TRH stimulates synthesis and release of prolactin. The **elevated TRH levels** in the pituitary in patients with primary hypothyroidism can therefore **increase prolactin secretion** and lead to hyperprolactinemia.

In premenopausal women, hyperprolactinemia can cause **galactorrhea**. Prolactin suppresses GnRH secretion from the hypothalamus, leading to reduced secretion of LH (and to a lesser extent FSH) and subsequent hypogonadism, anovulation, and **amenorrhea**. Symptoms in men are often nonspecific, but can include infertility, decreased libido, and impotence.

(Choices A and B) The most common cause of primary hypothyroidism is chronic autoimmune (Hashimoto) thyroiditis. Most patients with Hashimoto thyroiditis produce thyroid peroxidase autoantibodies, but it is TRH (not the autoantibodies) that triggers prolactin release.

(Choice C) Antidopaminergic drugs (eg, antipsychotics, metoclopramide) can reduce the inhibitory effect of dopamine on prolactin secretion and lead to hyperprolactinemia, but TSH has little effect on dopamine pathways.

(Choice E) The stimulatory effect of TRH on pituitary lactotrophs is mediated by TRH receptors on lactotroph cells, not by effects on dopaminergic pathways. Overproduction of dopamine would inhibit lactotroph activity.

Prolactin is regulated primarily by the inhibitory effects of dopaminergic neurons from the hypothalamus. However, lactotroph cells express TRH receptors, and TRH stimulates synthesis and release of prolactin. The **elevated TRH levels** in the pituitary in patients with primary hypothyroidism can therefore **increase prolactin secretion** and lead to hyperprolactinemia.

In premenopausal women, hyperprolactinemia can cause **galactorrhea**. Prolactin suppresses GnRH secretion from the hypothalamus, leading to reduced secretion of LH (and to a lesser extent FSH) and subsequent hypogonadism, anovulation, and **amenorrhea**. Symptoms in men are often nonspecific, but can include infertility, decreased libido, and impotence.

(Choices A and B) The most common cause of primary hypothyroidism is chronic autoimmune (Hashimoto) thyroiditis. Most patients with Hashimoto thyroiditis produce thyroid peroxidase autoantibodies, but it is TRH (not the autoantibodies) that triggers prolactin release.

(Choice C) Antidopaminergic drugs (eg, antipsychotics, metoclopramide) can reduce the inhibitory effect of dopamine on prolactin secretion and lead to hyperprolactinemia, but TSH has little effect on dopamine pathways.

(Choice E) The stimulatory effect of TRH on pituitary lactotrophs is mediated by TRH receptors on lactotroph cells, not by effects on dopaminergic pathways. Overproduction of dopamine would inhibit lactotroph activity.

(Choice F) Effects of the hypothalamic-pituitary-thyroid axis on prolactin secretion are mediated primarily by TRH, not TSH.

Educational objective:
Prolactin production is regulated primarily by inhibitory effects of hypothalamic dopaminergic pathways. However, prolactin secretion is stimulated by thyrotropin-releasing hormone (TRH). In patients with primary hypothyroidism, the increased production of TRH by the hypothalamus can lead to hyperprolactinemia.

References

- Role of thyrotropin-releasing hormone in prolactin-producing cell models.

Anatomy	Female Reproductive System & Breast	Hypothyroidism
Subject	System	Topic

Copyright © UWorld. All rights reserved.

1
2
3
4
5
6
7
8
9
10
11
12
13
14
15
16
17
18
19
20
21
22

A 23-year-old primigravida woman vaginally delivers a 3600-g (7 lb 15 oz) girl after a protracted labor. The patient sustains second-degree laceration and repair is planned. Prior to administering local anesthesia, the operator intravaginally palpates bony protrusions located posterolateral to the vaginal sidewalls that are distinct from the rest of the pelvic sidewall. A firm band can also be palpated running medially and posteriorly from the bony prominence to the sacrum. Anesthetic agent is injected around the bony prominence. Which of the following nerves is blocked by the injection?

A. Genitofemoral
B. Iliohypogastric
C. Inferior gluteal
D. Lateral femoral cutaneous
E. Obturator
F. Pudendal

Submit

A 23-year-old primigravida woman vaginally delivers a 3600-g (7 lb 15 oz) girl after a protracted labor. The patient sustains second-degree laceration and repair is planned. Prior to administering local anesthesia, the operator intravaginally palpates bony protrusions located posterolateral to the vaginal sidewalls that are distinct from the rest of the pelvic sidewall. A firm band can also be palpated running medially and posteriorly from the bony prominence to the sacrum. Anesthetic agent is injected around the bony prominence. Which of the following nerves is blocked by the injection?

- A. Genitofemoral (4%)
- B. Iliohypogastric (2%)
- C. Inferior gluteal (1%)
- D. Lateral femoral cutaneous (0%)
- E. Obturator (3%)
- ✓ F. Pudendal (88%)

Omitted
Correct answer
F

88%
Answered correctly

02 secs
Time Spent

06/23/2020
Last Updated

Explanation

Pelvic innervation		
Nerve	Origin	Function

Pelvic innervation		
Nerve	**Origin**	**Function**
Pudendal	S2-S4	Sensory: Perineum Motor: Urethral & anal sphincters
Lateral femoral cutaneous	L2-L3	Sensory: Anterior & lateral thigh
Inferior gluteal	L5-S2	Motor: Gluteus maximus
Genitofemoral	L1-L2	Sensory: Scrotum/labia majora, medial thigh
Obturator	L3-L4	Sensory: Medial thigh Motor: Adduction
Iliohypogastric	T12-L1	Sensory: Suprapubic

©UWorld

Local anesthesia may be administered if a woman has progressed too far in labor to receive epidural anesthesia. This patient is receiving a **pudendal nerve** (PN) block for perineal laceration repair. The PN is derived from the **S2-S4** nerve roots and provides sensory innervation to the **perineum and genitals**, as well as motor innervation to the sphincter urethrae and the external anal sphincter.

Important landmarks for a PN block include the **ischial spines** and **sacrospinous ligament**. The ischial spines are bony protrusions located posterolateral to the vaginal sidewall. The sacrospinous ligament is a firm band that runs medially and posteriorly from the ischial spine to the

©UWorld

Local anesthesia may be administered if a woman has progressed too far in labor to receive epidural anesthesia. This patient is receiving a **pudendal nerve** (PN) block for perineal laceration repair. The PN is derived from the **S2-S4** nerve roots and provides sensory innervation to the **perineum and genitals**, as well as motor innervation to the sphincter urethrae and the external anal sphincter.

Important landmarks for a PN block include the **ischial spines** and **sacrospinous ligament**. The ischial spines are bony protrusions located posterolateral to the vaginal sidewall. The sacrospinous ligament is a firm band that runs medially and posteriorly from the ischial spine to the sacrum. When administering a PN block, the ischial spines should be palpated intravaginally, and the anesthetic should be injected medially in very close proximity to the ischial spine through the sacrospinous ligament.

Other important structures include the **internal pudendal artery and inferior gluteal artery**, which run medial to the PN. Inadvertent injection into these vessels can lead to **hematoma** or arrhythmia from intravascular infiltration of local anesthetics (eg, lidocaine).

(Choices A, B, and E) Pelvic surgery carries the risk of several other neuropathies:

- The genitofemoral nerve courses along the anterior surface of the psoas muscle. Its branches innervate the scrotum/labia majora and the medial thigh. Injury from abdominal retractors during laparotomy can lead to labial/scrotal anesthesia.
- The iliohypogastric nerve innervates the suprapubic skin. Injury during closure of Pfannenstiel skin incisions (eg, cesarean section) can result in burning pain and paresthesias.
- The obturator nerve provides motor and sensory innervation to the medial thigh. Injury during retroperitoneal pelvic lymph node dissection can result in loss of medial thigh sensation and ability to adduct the thigh.

(Choice C) The inferior gluteal nerve innervates the gluteus maximus. Injury during hip surgery can impair hip extension.

(Choice D) The lateral femoral cutaneous nerve courses deep to the inguinal ligament to innervate the anterolateral thigh skin. It is commonly injured during hyperflexion of the thighs in the lithotomy position for pelvic surgery or a vaginal delivery. Complications include anterior and lateral thigh numbness (eg, meralgia paresthetica).

Educational objective:
A pudendal nerve block is performed by injecting an anesthetic intravaginally, medial to the ischial spine, through the sacrospinous ligament. This provides anesthesia to most of the perineum.

©UWorld

Exhibit Display

Pudendal nerve block

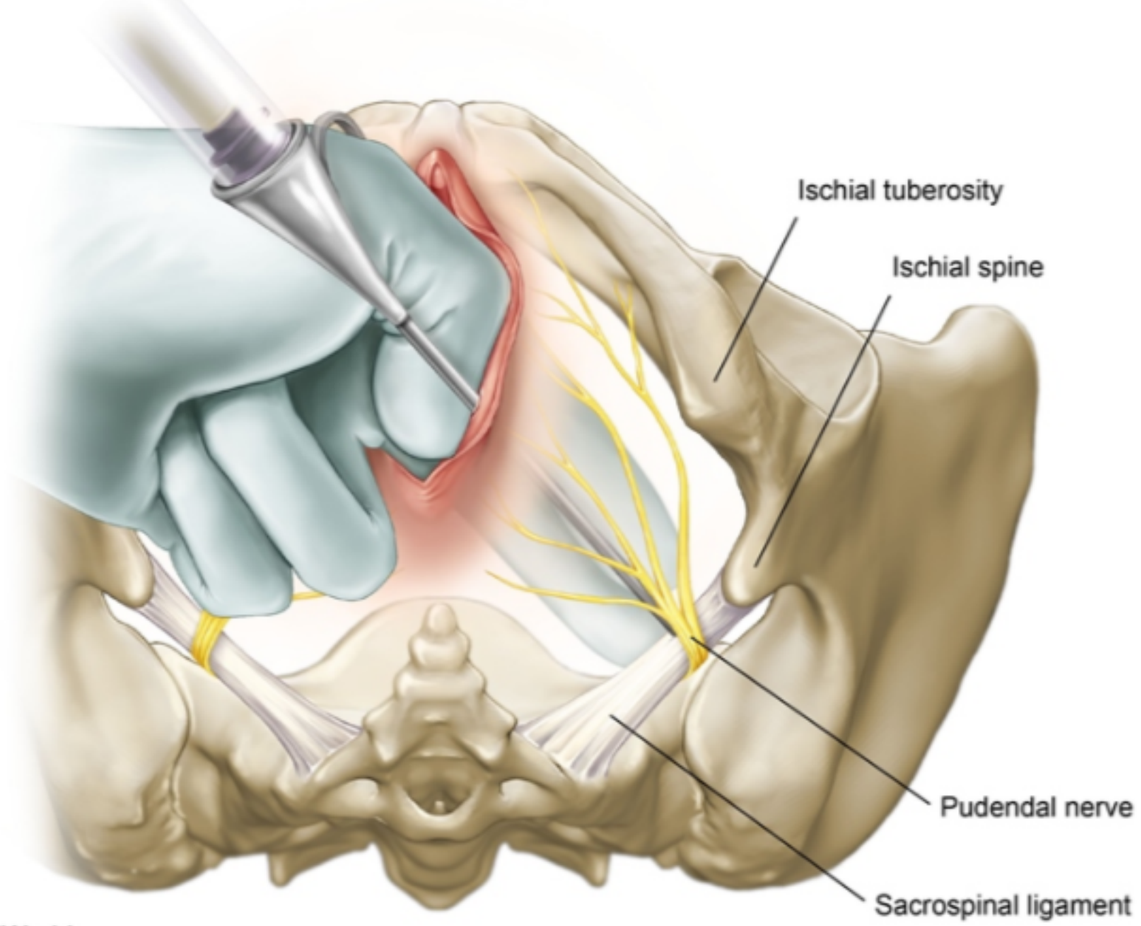

©UWorld

Zoom In | Zoom Out | Reset | Add To New Card | Existing Card

©UWorld

Exhibit Display

Abdominopelvic cutaneous innervation

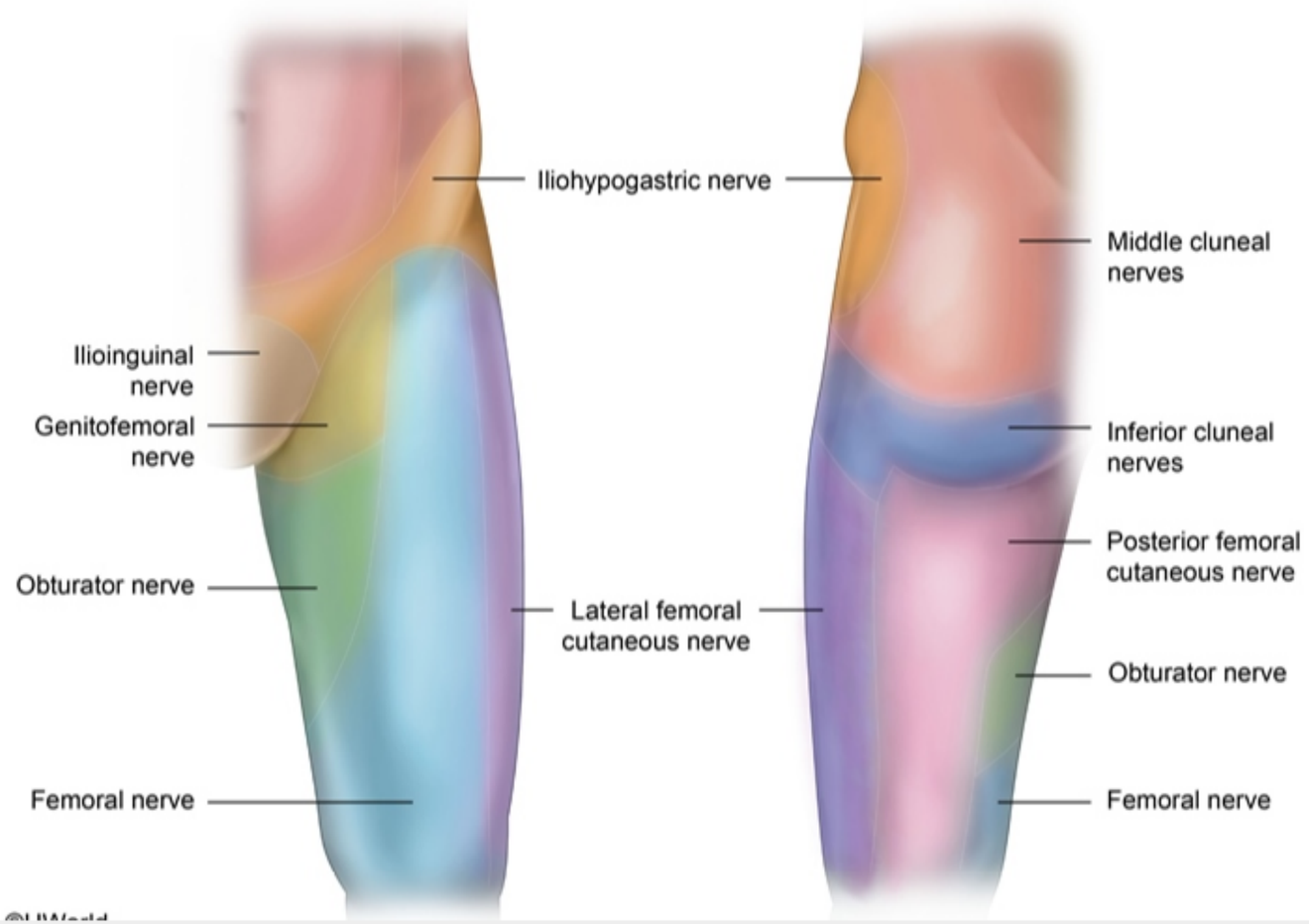

Zoom In | Zoom Out | Reset | Add To New Card | Existing Card

©UWorld

Exhibit Display

Lateral femoral cutaneous nerve & meralgia paresthetica

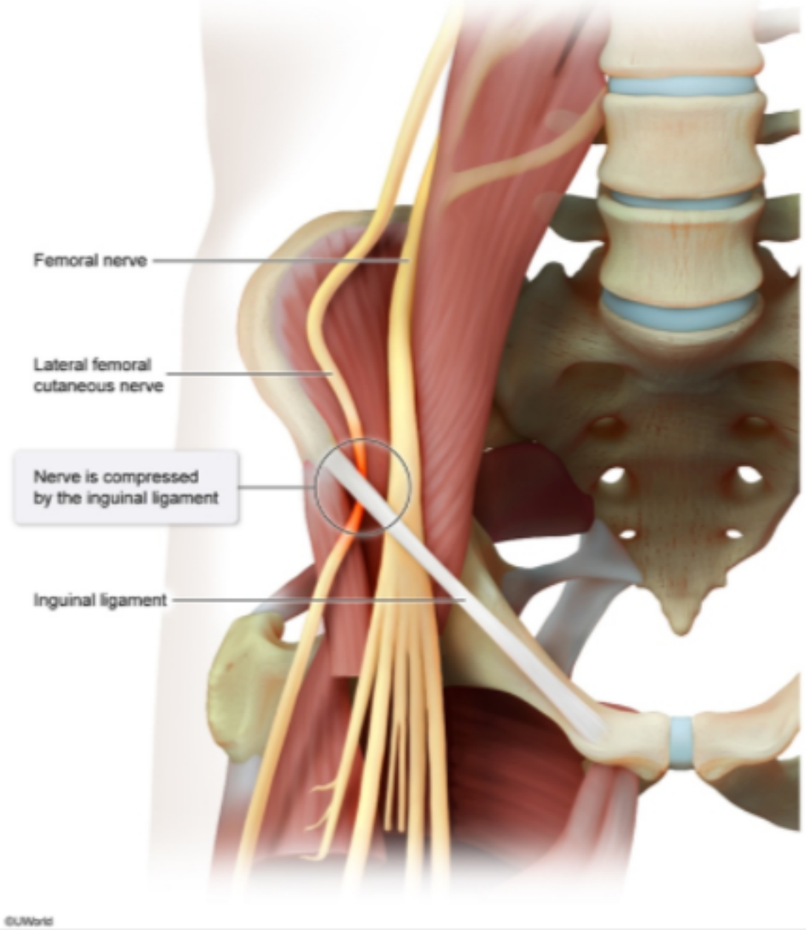

Zoom In | Zoom Out | Reset | Add To New Card | Existing Card

Other important structures include the **internal pudendal artery and inferior gluteal artery**, which run medial to the PN. Inadvertent injection into these vessels can lead to **hematoma** or arrhythmia from intravascular infiltration of local anesthetics (eg, lidocaine).

(Choices A, B, and E) Pelvic surgery carries the risk of several other neuropathies:

- The genitofemoral nerve courses along the anterior surface of the psoas muscle. Its branches innervate the scrotum/labia majora and the medial thigh. Injury from abdominal retractors during laparotomy can lead to labial/scrotal anesthesia.
- The iliohypogastric nerve innervates the suprapubic skin. Injury during closure of Pfannenstiel skin incisions (eg, cesarean section) can result in burning pain and paresthesias.
- The obturator nerve provides motor and sensory innervation to the medial thigh. Injury during retroperitoneal pelvic lymph node dissection can result in loss of medial thigh sensation and ability to adduct the thigh.

(Choice C) The inferior gluteal nerve innervates the gluteus maximus. Injury during hip surgery can impair hip extension.

(Choice D) The lateral femoral cutaneous nerve courses deep to the inguinal ligament to innervate the anterolateral thigh skin. It is commonly injured during hyperflexion of the thighs in the lithotomy position for pelvic surgery or a vaginal delivery. Complications include anterior and lateral thigh numbness (eg, meralgia paresthetica).

Educational objective:
A pudendal nerve block is performed by injecting an anesthetic intravaginally, medial to the ischial spine, through the sacrospinous ligament. This provides anesthesia to most of the perineum.

References

- Pudendal nerve block for vaginal birth.
- A randomized controlled trial of pudendal nerve block for pain relief after episiotomy.

Anatomy	Female Reproductive System & Breast	Anesthesia
Subject	System	Topic

Copyright © UWorld. All rights reserved.

A 39-year-old woman, gravida 2, para 2, is evaluated in the hospital after a total abdominal hysterectomy for symptomatic uterine fibroids. Hysterectomy was performed due to a history of heavy menses, abdominal fullness, and urinary incontinence. The largest fibroid, measuring 8 cm in diameter, was located in the lower aspect of the uterus at the level of the cardinal ligaments, compressing the bladder anteriorly. The patient has no other medical problems and no prior surgeries. Postoperatively, she has a fever and right-sided back pain. She has been able to urinate without any difficulty. Injury to which of the following structures is the most likely explanation for this patient's postoperative symptoms?

A. Bladder

B. External iliac artery

C. Ovarian artery

D. Ureter

E. Uterine artery

Submit

A 39-year-old woman, gravida 2, para 2, is evaluated in the hospital after a total abdominal hysterectomy for symptomatic uterine fibroids. Hysterectomy was performed due to a history of heavy menses, abdominal fullness, and urinary incontinence. The largest fibroid, measuring 8 cm in diameter, was located in the lower aspect of the uterus at the level of the cardinal ligaments, compressing the bladder anteriorly. The patient has no other medical problems and no prior surgeries. Postoperatively, she has a fever and right-sided back pain. She has been able to urinate without any difficulty. Injury to which of the following structures is the most likely explanation for this patient's postoperative symptoms?

- A. Bladder (2%)
- B. External iliac artery (3%)
- C. Ovarian artery (10%)
- ✓ D. Ureter (63%)
- E. Uterine artery (19%)

Omitted
Correct answer
D

63%
Answered correctly

02 secs
Time Spent

02/17/2020
Last Updated

Explanation

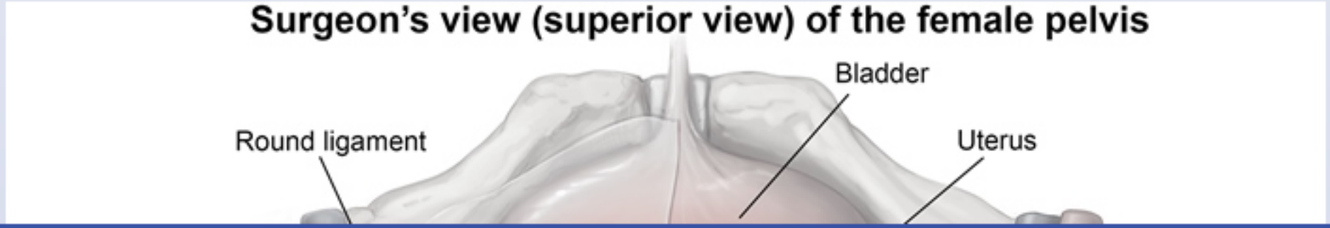

Surgeon's view (superior view) of the female pelvis

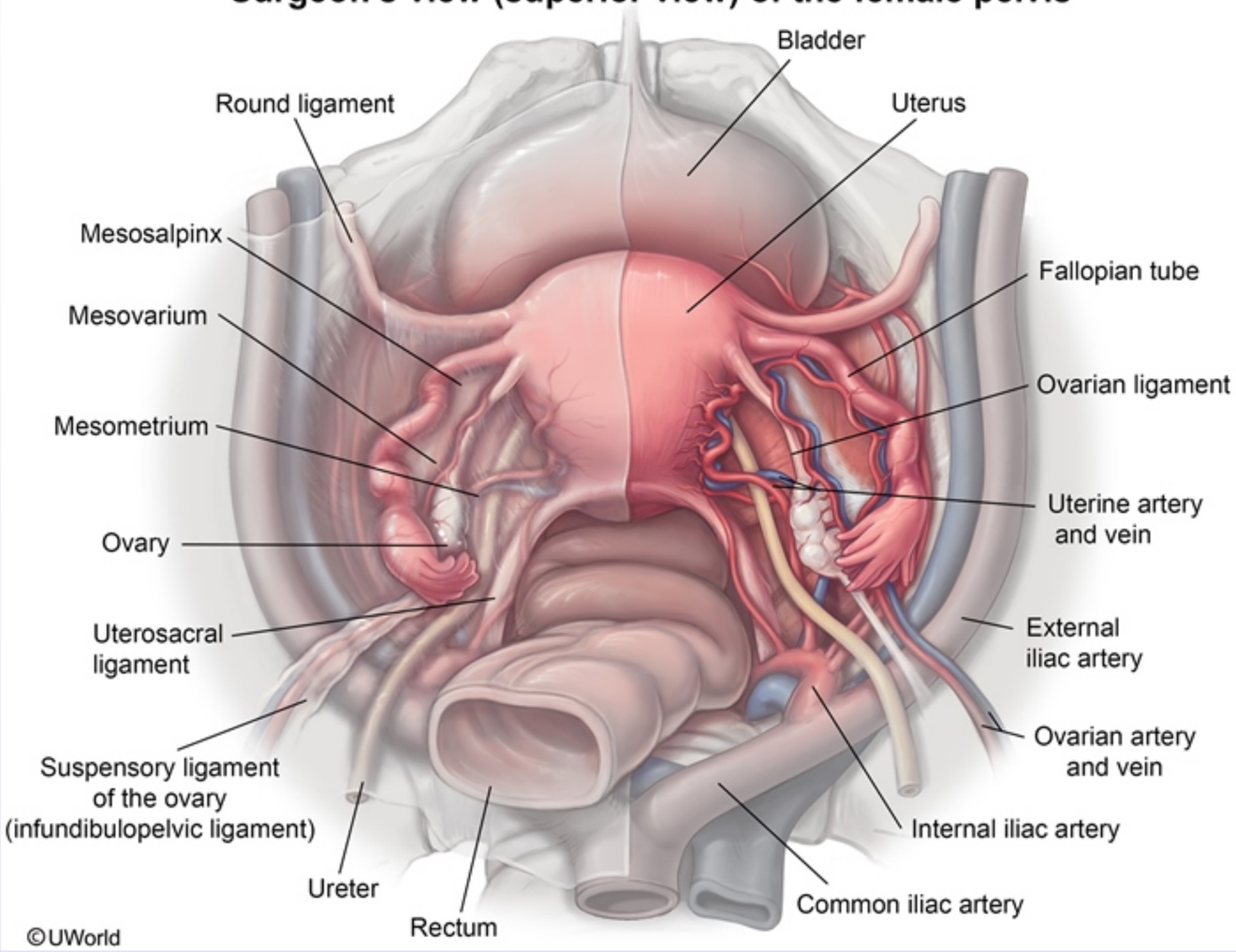

This patient has a right **ureteral injury**, a rare but serious complication of pelvic surgery presenting with **flank pain** and **fever.** The ureter is a retroperitoneal structure that arises from the renal pelvis and enters the trigone at the posterior aspect of the urinary bladder, with equal proportions in the abdomen and pelvis. The pelvic portion starts at the level of the pelvic brim, and courses medially and anteriorly to the

This patient has a right **ureteral injury**, a rare but serious complication of pelvic surgery presenting with **flank pain** and **fever.** The ureter is a retroperitoneal structure that arises from the renal pelvis and enters the trigone at the posterior aspect of the urinary bladder, with equal proportions in the abdomen and pelvis. The pelvic portion starts at the level of the pelvic brim, and courses medially and anteriorly to the bifurcation of the common iliac arteries. Then, the ureter passes along the lateral pelvic sidewall posterior to the ovarian vessels to dive under the uterine vessels ("**water under the bridge**"= ureter carrying water, the uterine vessels signifying the bridge). Finally, it runs along the anterolateral surface of the cervix at the level of the internal os to enter the bladder trigone.

The ureter is most vulnerable to injury during a **hysterectomy**, where the damage can occur at the point of ligation of the uterine vessels and closure of the lateral aspects of the vaginal cuff. This patient was at increased risk for injury secondary to a large fibroid close to the course of the distal ureter. A ureteral obstruction injury with a suture leads to flank pain due to distention of the proximal ureter with urine. A transection injury of the ureter causes localized leakage of urine as well as flank pain. Since the **second ureter is uninjured**, patients are able to **void (urinate) normally**. Bilateral ureteral injury is extremely unlikely and would result in anuria and bilateral flank pain.

(Choice A) The bladder can be injured in a hysterectomy during its separation from the lower aspect of the uterus and cervix. This patient is at risk for bladder injury given the distorted uterine anatomy, but a bladder injury would present with urinary symptoms (dysuria, hematuria, or anuria) and not unilateral flank pain.

(Choices B and C) The external iliac and ovarian arteries are not manipulated during a hysterectomy and are not typically at risk for injury. The ovarian vessels are ligated when an oophorectomy is performed, and the point of ligation is a potential area for ureteral injury. However, this patient did not undergo an oophorectomy.

(Choice E) The uterine vessels, which contain the main uterine blood supply, are ligated during a hysterectomy. Ligation may be difficult in the setting of a large fibroid. Unrecognized insufficient ligation may lead to hemorrhage, which would present postoperatively as an acute abdomen with hypotension, tachycardia, and dizziness.

Educational objective:
The ureter can be injured during hysterectomy due to its close proximity to the uterine structures. The distal ureter may be severed during ligation of the uterine vessels because the ureter passes inferior and lateral to the uterine artery at the level of the internal cervical os prior to entering the bladder (eg, "water under the bridge").

References

closure of the lateral aspects of the vaginal cuff. This patient was at increased risk for injury secondary to a large fibroid close to the course of the distal ureter. A ureteral obstruction injury with a suture leads to flank pain due to distention of the proximal ureter with urine. A transection injury of the ureter causes localized leakage of urine as well as flank pain. Since the **second ureter is uninjured**, patients are able to **void (urinate) normally**. Bilateral ureteral injury is extremely unlikely and would result in anuria and bilateral flank pain.

(Choice A) The bladder can be injured in a hysterectomy during its separation from the lower aspect of the uterus and cervix. This patient is at risk for bladder injury given the distorted uterine anatomy, but a bladder injury would present with urinary symptoms (dysuria, hematuria, or anuria) and not unilateral flank pain.

(Choices B and C) The external iliac and ovarian arteries are not manipulated during a hysterectomy and are not typically at risk for injury. The ovarian vessels are ligated when an oophorectomy is performed, and the point of ligation is a potential area for ureteral injury. However, this patient did not undergo an oophorectomy.

(Choice E) The uterine vessels, which contain the main uterine blood supply, are ligated during a hysterectomy. Ligation may be difficult in the setting of a large fibroid. Unrecognized insufficient ligation may lead to hemorrhage, which would present postoperatively as an acute abdomen with hypotension, tachycardia, and dizziness.

Educational objective:
The ureter can be injured during hysterectomy due to its close proximity to the uterine structures. The distal ureter may be severed during ligation of the uterine vessels because the ureter passes inferior and lateral to the uterine artery at the level of the internal cervical os prior to entering the bladder (eg, "water under the bridge").

References

- Urinary tract injuries: recognition and management.
- Urinary tract injury during hysterectomy based on universal cystoscopy.

Anatomy	Female Reproductive System & Breast	Ureter injury
Subject	System	Topic

Copyright © UWorld. All rights reserved.